



## Anti-N-Methyl-D-Aspartate-Receptor Encephalitis, a Challenge for Neurologists or a Chameleon for Psychiatrists: A Case Report

Ghabeli-Juibary Ali (MD)<sup>1</sup>, Rezaei-Ardani Amir (MD)<sup>2</sup>, Rezaeitab Fariborz (MD)<sup>3\*</sup>, Verdipoor Mahdieh (MD)<sup>4</sup>

### ARTICLE INFO

#### Article type:

Case Report

#### Article history:

Received: 28 June 2015

Accepted: 30 June 2015

Available online: 9 July 2015

CJNS 2015; 1 (2): 52-55

1. Resident of Neurology, Department of Neurology, Student Research Committee, School of Medicine, Mashhad University of Medical Sciences, Mashhad, Iran

2. Assistant professor of psychiatry, Psychiatry and Behavioral Sciences Research Center, Mashhad University of Medical Sciences, Mashhad, Iran

3. Assistant professor of Neurology, Department of Neurology, School of Medicine, Mashhad University of Medical Sciences, Mashhad, Iran

4. Resident of Neurology, Department of Neurology, Student Research Committee, School of Medicine, Mashhad University of Medical Sciences, Mashhad, Iran

#### \*Corresponding author:

Assistant professor of Neurology, Department of Neurology, School of Medicine, Mashhad University of Medical Sciences, Mashhad, Iran

Email: rezaeitabf@mums.ac.ir

### ABSTRACT

Anti-N-Methyl-D-Aspartate-Receptor (NMDA-R) encephalitis is a new autoimmune disorder, often paraneoplastic in nature, presenting with complex neuropsychiatric symptoms. Diagnosed serologically, this disorder is often responsive to immunosuppressant treatment.

We here in report the case of a 56-year-old man with anti NMDA-R encephalitis presenting initially with disorientation and hallucination. He later developed bilateral ophthalmoplegia and spastic tetraparesis. Neurological examination showed mild consciousness disturbance and bilateral ophthalmoplegia on admission, spastic tetraparesis with limbs hyperreflexia. Cerebrospinal fluid samples showed mild pleocytosis. MRI disclosed some small hypersignal lesions in the FLAIR. Anti-NMDA-R antibody was diagnosed upon detection of antibody in the serum.

Psychiatrists and neurologists should pay more attention to the cranial, mental and behavioral involvement due to this potentially fatal disease.

**Keywords:** Anti-N-Methyl-D-Aspartate Receptor Encephalitis; Disease Management; Complications

Copyright © 2015 Caspian Journal of Neurological Sciences. All rights reserved.

#### ➤ Please cite this paper as:

Ghabeli-Juibary A, Rezaei-Ardani A, Rezaeitab F, Verdipoor M. Anti-N-Methyl-D-Aspartate-Receptor Encephalitis, a Challenge for Neurologists or a Chameleon for Psychiatrists: A Case Report. Caspian J Neurol Sci 2015; 1(2):52-55.

## Introduction

Anti N-Methyl-D-Aspartate-Receptor (NMDA-R) encephalitis is a type of acute autoimmune encephalitis. It was first identified in four women with

ovarian teratoma who presented with psychiatric symptoms, memory loss, altered levels of consciousness, and central hypoventilation in 2005 (1,2,3). Even with the

severe disease, patients often recover after immunotherapy, and lengthy stays in hospital with intensive care management.

Clinical picture is an amalgam of psychiatric and neurological symptoms and signs. Patients may experience prodromal symptoms like headaches and flu-like illness several weeks prior to disease onset. The disease usually presents with psychiatric symptoms including cognitive impairment and behavioral disturbances (e.g. psychotic symptoms, catatonic features), which may lead to unnoticed illness. Soon after, symptoms extend to neurological problems such as abnormal rhythmic movements (orofacial dyskinesias, choreoathetosis), seizures, aphasia, cerebellar ataxia, hemiparesis, hypoventilation and loss of consciousness. This scenario should prompt testing for anti-bodies against the GluN1 subunit of the NMDA-R, especially in young individuals (4,5).

Identification of NMDA-R antibodies confirms the diagnosis of the disorder and should lead to the search for a tumor, which, if present, is almost always an ovarian teratoma that contains nervous tissue and expresses NMDA-R. Immunomodulatory treatment can save the patient's life (6).

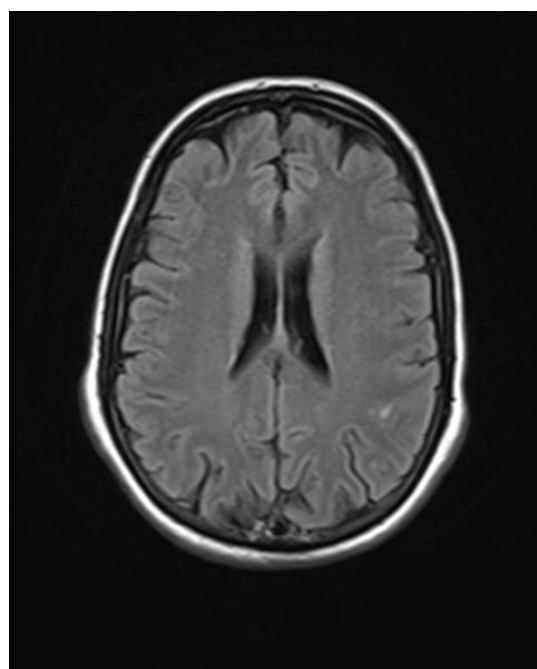
We herein report a male patient with ophthalmoplegia, spastic tetraparesis and unconsciousness state during the course of anti-NMDAR encephalitis.

### Case Presentation

The patient, a 56 year old male, admitted to emergency neurology ward of Ghaem hospital (Mashhad-Iran) with subacute confusional state. Neurologic exam revealed bilateral ophthalmoplegia, spastic tetraparesis

and disorientation. His temperature was 37.4°C. General examination was otherwise normal. He had a 3 week history of gradually altered mood with disturbances in behavior before developing the full condition.

Brain MRI disclosed some small hypersignal lesions in the fluid attenuated inversion recovery (FLAIR) images (Figure 1) with no enhancement in T1 weighted images after intravenous injection of gadolinium. Cervical MRI was normal.



**Figure 1:** Two hyperintense lesions were found on FLAIR sequences on corticomedullary junction of parietal lobe

Cerebrospinal fluid (CSF) samples showed mild pleocytosis (predominantly mononuclear) with slightly increased content of protein. Investigation for evidences of brucellosis (wright and 2-mercaptoethanol brucella agglutination test), tuberculosis and herpes simplex (PCR) in the CSF were negative. As autoimmune encephalitis became suspected, the serum was sent for autoimmune antibodies.

*Clinical course and treatment:* The condition deteriorated before confirming the diagnosis. Therefore, the patient underwent empiric therapy for bacterial meningitis and viral encephalitis. Also, because of no response and high suspicion of autoimmune encephalitis, a course of Intra Venous Immunoglobulin (IVIg) (2 g/kg divided over 5 days) was commenced. Serial CSF samples showed a non-specific lymphocytic pleocytosis.

Fourteen days following admission, he developed sepsis with hemodynamic failure. Consistent with advanced directives, cardiopulmonary resuscitation was not effective and our patient passed away. After that among a list of antibodies for autoimmune encephalitis, the serum NMDA-R antibody tested before his death was reported as positive.

## Discussion

The eminence of psychiatric symptoms in anti-NMDA-R encephalitis has been of remarkable curiosity to the psychiatrists by raising the opportunity to an identifiable, treatable type of psychiatric disorder (6,7). The group of symptoms in anti-NMDA-R encephalitis results in a characteristic syndrome that can imply different diagnoses at diverse stages. Patients, particularly adults, are often diagnosed with new onset psychotic disorder (7,8,9). Drugs that block NMDA-R function, such as phencyclidine, can produce similar presentation (10).

Assessment of near 600 cases has shown that, while rare, some patients may display only psychiatric symptoms without any neurological signs during the first disease episode or in a relapse episode (7). Delayed diagnosis can prolong immunosuppressant initiation and lead to a more severe syndrome,

which can result in hypoventilation, coma, or status epilepticus. These severe cases are often treated for extended periods of time in an intensive care unit (6,7). This observation stresses the importance of prompt diagnosis and treatment, with emphasis on supportive care (8,9).

The detection of anti-NMDA-R encephalitis has altered the diagnostic and therapeutic approach to several psychiatric and neurological disorders. It has led to the identification of an increasing cluster of autoimmune encephalitis related to antibodies against synaptic proteins (8,10). Rapidly progressive alterations of consciousness, memory, orientation, behavior and development of psychotic symptoms (hallucinations or delusions) previously thought to be idiopathic or because of viral infection are now documented to be autoimmune in nature (11,12,13).

To our knowledge, the clinical syndrome in anti-NMDA-R encephalitis comprises psychotic symptoms, suggesting that autoimmunity involving IgG GluN1 antibodies results in a schizophrenia-like state though one progressing to include severe neurological involvement in most cases (2).

Management of anti-NMDA-R encephalitis has to initially focus on immunotherapy and the detection and elimination of a teratoma. Most patients take corticosteroids, plasma exchange or intravenous immunoglobulins (IVIg) as first-line of immunotherapy (2).

## Conclusion

We highlighted a male patient with anti-NMDAR encephalitis and unremarkable MRI findings. Psychiatrists and neurologists should pay more attention to the cranial, mental and behavioral involvement. Further

clinical and immunological laboratory assessment is needed to clarify the full spectrum of anti-NMDA-R encephalitis or its partial overlapping with other neurological autoimmune disorders.

### Conflict of Interest

No conflict of interest.

### References

- Vitaliani R, Mason W, Ances B, Zwerdling T, Jiang Z, Dalmau J. Paraneoplastic Encephalitis, Psychiatric Symptoms, and Hypoventilation in Ovarian Teratoma. *Ann Neurol* 2005; 58(4):594-604.
- Titulaer MJ, McCracken L, Gabilondo I, Armangué T, Glaser C, Iizuka T, et al. Treatment and Prognostic Factors for Long-Term Outcome in Patients with anti-NMDA Receptor Encephalitis: an Observational Cohort Study. *Lancet Neurol* 2013;12(2): 157–165.
- Dalmau J, Lancaster E, Martinez-Hernandez E, Rosenfeld MR, Balice-Gordon R. Clinical Experience and Laboratory Investigations in Patients with anti-NMDAR Encephalitis. *Lancet Neurol* 2011; 10(1):63–74.
- Pruss H, Dalmau J, Harms L, Holtje M, Ahnert-Hilger G, Borowski K, et al. Retrospective Analysis of anti-Glutamate Receptor (type NMDA) Antibodies in Patients with Encephalitis of Unknown Origin. *Neurology* 2010; 75: 1735–39.
- Dalmau J, Gleichman AJ, Hughes EG, Rossi JE, Peng X, Lai M, et al. Anti-NMDA-Receptor Encephalitis: Case Series and Analysis of the Effects of Antibodies. *Lancet Neurol* 2008; 7(12):1091-8.
- Wandinger KP, Saschenbrecker S, Stoecker W, Dalmau J. Anti-NMDA-Receptor Encephalitis: a Severe, Multistage, Treatable Disorder Presenting with Psychosis. *J Neuroimmunol* 2011; 231(1-2):86–91.
- Kayser MS, Titulaer MJ, Gresa-Arribas N, Dalmau J. Frequency and Characteristics of Isolated Psychiatric Episodes in anti-N-methyl-D-Aspartate Receptor Encephalitis. *JAMA Neurol* 2013; 70(9):1133-9.
- Steiner J, Walter M, Glanz W, Sarnyai Z, Bernstein HG, Vielhaber S, et al. Increased Prevalence of Diverse N-methyl-D-aspartate Glutamate Receptor Antibodies in Patients with an Initial Diagnosis of Schizophrenia: Specific Relevance of IgG NR1a Antibodies for Distinction from N-methyl-D-aspartate Glutamate Receptor Encephalitis. *JAMA Psychiatry* 2013; 70(3):271-8.
- Lancaster E, Lai M, Peng X, Hughes E, Constantinescu R, Raizer J, et al. Antibodies to the GABA(B) Receptor in Limbic Encephalitis with Seizures: Case Series and Characterization of the Antigen. *Lancet Neurol* 2010; 9(1):67-76.
- McCarron MM, Schulze BW, Thompson GA, Conder MC, Goetz WA. Acute Phencyclidine Intoxication: Incidence of Clinical Findings in 1,000 Cases. *Ann Emerg Med* 1981; 10(5):237-42.
- Lebas A, Husson B, Didelot A, Honnorat J, Tardieu M. Expanding Spectrum of Encephalitis with NMDA Receptor Antibodies in Young Children. *J Child Neurol* 2010; 25(6):742-5.
- Shimazaki H, Morita M, Nakano I, Dalmau J. Inverse Ocular Bobbing in a Patient with Encephalitis Associated with Antibodies to the N-Methyl-D-Aspartate Receptor. *Arch Neurol* 2008; 65(9):1251.
- Ferioli S, Dalmau J, Kobet CA, Zhai QJ, Broderick JP, Espay AJ. Anti-N-Methyl-D-Aspartate Receptor Encephalitis: Characteristic Behavioral and Movement Disorder. *Arch Neurol* 2010; 67(2):250-1.