

## Headache: A Presentation of Pompe Disease; A Case Report

Rezaeitalab Fariborz (MD)<sup>1</sup>, Boostani Reza (MD)<sup>2</sup>, Ghabeli-Juibary Ali (MD)<sup>3</sup>, Mali Sara (MD)<sup>4\*</sup>

### ARTICLE INFO

**Article type:**  
Case Report

### Article history:

Received: 29 October 2016  
Accepted: 25 February 2017  
Available online: 30 February 2017  
CJNS 2017; 3 (8): 54-59  
DOI:  
<https://doi.org/10.18869/acadpub.cjns.3.8.54>

1. Assistant Professor, Department of Neurology, School of Medicine, Mashhad University of Medical Sciences, Mashhad, Iran
2. Associate Professor, Department of Neurology, School of Medicine, Mashhad University of Medical Sciences, Mashhad, Iran
3. Neurologist, Student Research Committee, School of Medicine, Mashhad University of Medical Sciences, Mashhad, Iran
4. Resident of Neurology, Department of Neurology, School of Medicine, Mashhad University of Medical Sciences, Mashhad, Iran

### \*Corresponding author:

Resident of Neurology, Department of Neurology, School of Medicine, Mashhad University of Medical Sciences, Mashhad, Iran  
Email: malisara46@yahoo.com

### ABSTRACT

Pompe disease, also termed glycogen storage disease type II or acid maltase deficiency, caused by deficient activity of acid alpha-glucosidase (GAA), the glycogen degrading lysosomal enzyme. As a result, massive lysosomal glycogen deposits in the numerous organs including the muscles. In Pompe disease weakness of truncal muscles is a prominent presentation which results in respiratory failure as a main clinical presentation in the early stages of the disease. Even sleep may be affected by nocturnal respiratory disturbances. Specific treatment with enzyme replacement (human recombinant GAA) is available.

Here we present a case of progressive muscular weakness which had been misdiagnosed with limb girdle muscular dystrophy. A history of severe morning headaches led authors to think about sleep apnea, which was confirmed by polysomnography and therefore provided a clue for appropriate diagnosis of Pompe disease.

As a conclusion, Morning headaches and sleep insufficiency in any stage of a progressive muscular disorder can lead us to think about respiratory muscle involvement, which is more prominent in Pompe disease.

**Keywords:** Pompe Disease; Sleep Apnea, Obstructive; Lysosomal Storage Diseases; Headache

Copyright © [2017] Caspian Journal of Neurological Sciences. All rights reserved.

### ➤ Please cite this paper as:

Rezaeitalab F, Boostani R, Ghabeli-Juibary A, Mali S. Morning Headache: A Presentation of Pompe Disease; A Case Report. Caspian J Neurol Sci 2017; 3(8):54-59.

## Introduction

Pompe disease, also termed glycogen storage disease type II or acid maltase deficiency is an autosomal recessive disorder caused by deficient activity of acid alpha-glucosidase (GAA), the glycogen degrading lysosomal enzyme. As a result, massive lysosomal glycogen deposits in the

numerous organs of affected individuals including the muscles [1].

The level of residual GAA enzyme activity determines disease severity. According to age of onset and clinical presentation two forms of have been categorized: infantile form, with very low if not enzyme activity, presented

with severe muscle weakness and cardiomyopathy in the first month of life [2], and late onset Pompe disease (LOPD) may develop at any age from early childhood to adulthood and primarily involves proximal limbs and axial muscles [3,4]. The muscles may seem hypertrophied in spite of significant weakness [5]. The prevalence of Pompe disease has been estimated between 1 in 40,000 to 1 in 600,000 [6].

Pompe disease is unique among neuromuscular disorders as truncal muscles weakness is a prominent presentation. Accordingly, respiratory failure is a main clinical presentation in the early stages of the disease and the major cause of death in the course of disease [7,8]. Also, sleep may be affected by nocturnal respiratory disturbances resulted in daytime symptoms like morning headache and excessive daytime sleepiness [4,7]. In about one third of adult cases, the primary presentation is symptoms related to respiratory insufficiency like exertional dyspnea and recurrent pulmonary infections. However, slight limb weakness usually precedes respiratory insufficiency. With disease progression, the respiratory symptoms increase resulting in decreased vital capacity, sleep disordered breathing (SDB) including sleep apneas, sleep fragmentation and finally cor pulmonale [8,9].

Some myopathies have not truncal muscle involvement and have not sleep apnea, too. They are consisting of distal muscular dystrophy and Inclusion body myositis [1].

Morning or nocturnal headaches and daytime sleepiness are common presentations of sleep apneas [10]. According to international headache society (HIS), sleep apnea headache is defined as more than 15 days of month headache on awakening accompanied by polysomnographic

confirmed apnea-hypopnea index (AHI) of more than 5 per hour of sleep [11].

Because of low prevalence and a wide range of clinical symptoms, many cases go unrecognized. It should be differentiated from muscular dystrophies and other causes of chronic muscle weakness [6,12].

Here, we report a case of adult Pompe disease that had misdiagnosed with polyomyositis for years, but morning headaches due to recurrent sleep apnea and decreased sleep efficacy guided us to appropriate diagnosis and treatment.

### Case Presentation

A 29 year old lady, with a history of limb weakness, presented to our clinic with chronic morning headaches. She described her headaches as dull, without nausea, vomiting, visual blurring, photophobia or phonophobia. The headaches had not responded to pain killers and often subsided spontaneously after 3-4 hours of a wakening. In the past history, she had suffered from gradually progressive limb weakness since 7 years ago. The weakness was more prominent in the neck, the trunk and the proximal of limbs. She had difficulty in arising from the floor and climbing stairs without the assistance of the arms. During the past 7 years, she had not experienced an efficient nocturnal sleep. Four months ago she had a respiratory insufficiency attack led to admitting to intensive care unit (ICU), where tracheostomy was done for her.

She had a course of prednisone therapy with the diagnosis of polymyositis 2 years ago, without evidence of therapeutic effect. Eventually, with the diagnosis of limb girdle muscular dystrophy, she had been managed.

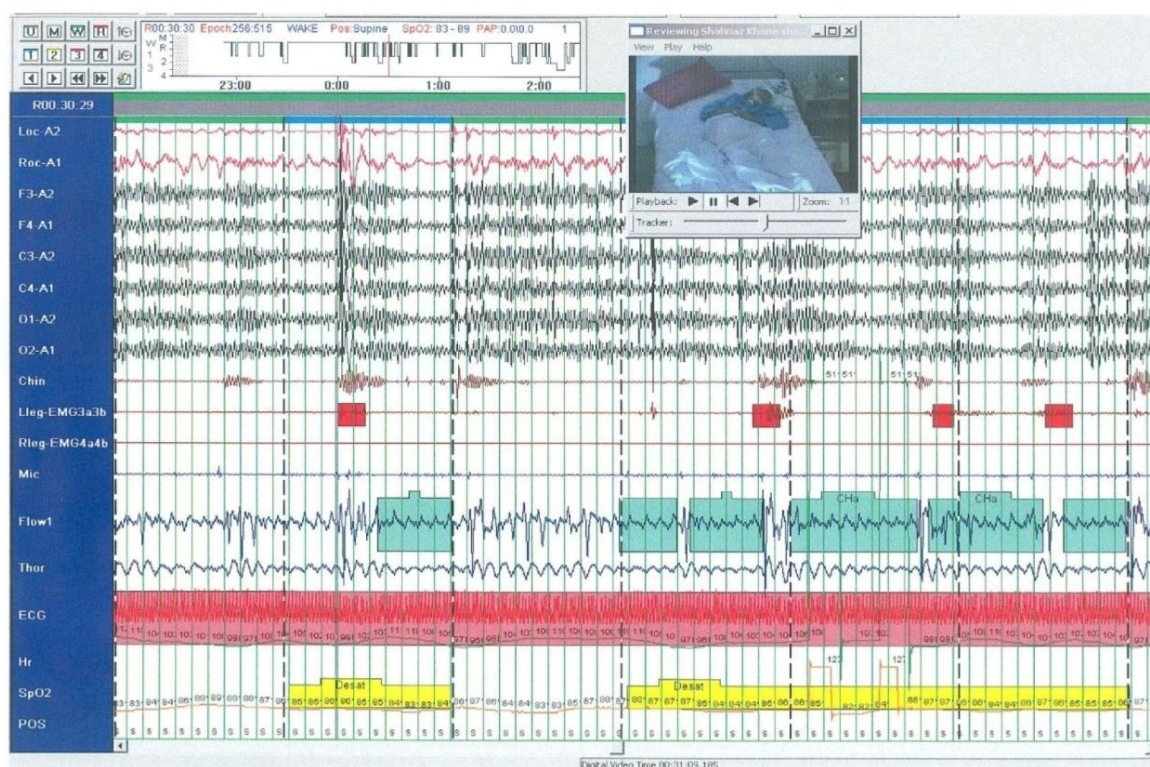
There was no family history of muscle disease, headaches or respiratory problems.

Neurological examination revealed severe weakness of the sternocleidomastoid muscles, severe wasting and weakness of the arm abductors (two of five score), proximal leg muscles (the hip flexors, extensors and adductors: two of five score), and bilateral mild weakness of dorsal flexors of the foot (four of five score). Otherwise the neurological examination including fundoscopy was normal. Cervical tenderness was not detected.

Routine laboratory tests revealed moderate elevated serum creatine phosphokinase (582 IU/L, normal range 10–100 IU/L) and lactate dehydrogenase (565 BBU/ml, normal range 150–500 BBU/ml). Brain MRI did not reveal any pathologic finding. Opening

pressure on lumbar puncture was 16 cm H<sub>2</sub>O and CSF analysis showed a protein of 40 mg/dl, sugar of 68 mg/dl (concurrent blood sugar: 98 mg/dl) and 0-1 white blood in mm<sup>3</sup>. Electromyography showed myopathic pattern.

Because of morning headaches and decreased sleep efficiency in the context of muscle weakness, she underwent an overnight polysomnography as a standard sleep study which revealed abnormal parameters. Her sleep efficacy was 27.09%. Severe hypoxemia, severe sleep apnea (AHI=77.56 per hour of sleep), severe respiratory-related arousal index (76.54 per hour of sleep) were also shown. A 3 minute epoch of the polysomnographic record is demonstrated below as figure 1.



**Figure 1.** An example of polysomnography recording of the patient. The yellowish marked areas represent oxygen desaturation and the green labeled areas represent hypopnea in a 3 minute epoch.

During the sleep study, an optimal pressure of NIV by mode of BiPAP with 110/70 Cm H<sub>2</sub>O pressure was achieved to correct the respiratory events. After one week using of BiPAP, the headaches subsided.

Although the patient was not ambulatory without assistance and after 10 years of disease her affected muscles were significantly atrophied, because of dramatic respiratory muscle involvement resulting in sleep disordered breathing, we investigated for the most common neuromuscular disorder which affect the truncal muscles, Pompe disease. The activities of alpha-glucosidase at PH 3.8, with and without specific inhibition, are 1.18, below their respective reference ranges (1.5-10 nmol/spot\*21h). A genetic test was also done which confirmed the diagnosis of late-onset Pompe disease with the homogenous mutation of c.[−32 − 13T > G]; [2608C > T].

Treatment with enzyme replacement therapy (Myozyme) every two weeks resulted in reduced disease progression. She has been also successfully on BiPAP therapy and supportive treatment including physiotherapy.

## Discussion

We are reporting an adult case of Pompe disease whose diagnosis was made after 10 year delay. According to literatures, more than five year delay in diagnosis has been accounted for more than half of the cases of LOPD [6]. The main causes of late diagnosis are broad spectrum phenotypes of disease and its low prevalence. Because of available treatment which is more effective in the early stages of this disease, awareness of the main presentations, particularly respiratory symptoms, is of great importance for neurologists.

Here, morning headaches, which could be attributed to sleep disordered breathing (SDB), turned on a light for us to discover the nature of the pathologic weakness, in spite of severe weakness due to delayed diagnosis. It is of value to emphasis that morning headaches without photophobia, phonophobia, visual disturbances, or vomiting may be a manifestation of SDB [10]. A literature review revealed that one third of LOPD may present with symptoms related to respiratory muscle involvement and in two third of Pompe cases respiratory symptoms develop as the disease progress [6]. A report on Iranian LOPD individuals showed that three out of 13 patients suffered from morning headaches and diurnal sleepiness due to SDB [13]. Another study conducted in Hong Kong calculated that half of their patients sought medical help for shortness of breathing [14]. The headaches may be attributed to nocturnal recurrent hypoxemia, sleep fragmentation or increase arousals during sleep [10]. In our case, recurrent sleep apneas were shown to be responsible for headaches, as treatment with CPAP removed the headaches after one week. Even in some reported cases of Pompe disease, upper airway muscles are the most involved muscles resulted in obstructive sleep apnea as a and first presentation [7].

Untreated Pompe disease may result in acute respiratory failure, unlike other neuromuscular disorders in which such event is presented in very late stages [15]. Our patient also experienced ICU admitting because of acute respiratory failure.

Appropriate non-invasive ventilation (NIV) can improve nocturnal respiration without undesired effect on sleep quality [6,16]. Specific treatment with enzyme replacement (human recombinant GAA) is



available [17], which highlights the importance of early diagnosis. In addition, appropriate management of respiratory disturbances with non-invasive positive pressure ventilation (NIPPV) and assisted coughing is able to improve the prognosis [7,8]. Patients with nocturnal hypoventilation and sleep apnea headache may also benefit from NIPPV through reduced daytime symptoms including morning headache and sleepiness [7].

Similarly, our patient's headaches responded appropriately to NIV treatment for sleep apnea. The patient has also received enzyme replacement. A systemic review showed that enzyme replacement therapy was associated with an increase of 1.4 % FVC after 2 months [17]. Because of such effective treatments, physicians are advised to be informed about various presentation of Pompe disease, especially respiratory insufficiency as an essentially fatal condition [18].

## Conclusion

Morning headaches and sleep insufficiency in a progressive muscular disorder can provide a clue to think about respiratory muscle involvement. Although these symptoms are frequently seen in late stages of neuromuscular disorders, Pompe disease should be taken into consideration in this context because of its treatable nature.

## Conflict of Interest

The authors have no conflict of interest.

## References

1. Ropper AH, Samuels MA, Klein JP. Diseases of Muscle. Adams and Victor's Principles of Neurology. 10<sup>th</sup> ed. New York; McGraw-Hill; 2014.
2. Kishnani PS, Hwu WL, Mandel H, Nicolino M, Yong F, Corzo D, et al. Infantile-Onset Pompe Disease Natural History Study Group: A Retrospective, Multinational, Multicenter Study on the Natural History of Infantile-Onset Pompe Disease. *J Pediatr* 2006; 148(5):671-6.
3. Preston DC, Shapiro BE. Myopathy. Electromyography and Neuromuscular disorders. 3<sup>rd</sup> ed. London; Elsevier; 2013.
4. Kishnani PS, Steiner RD, Bali D, Berger K, Byrne BJ, Case LE, et al. Pompe Disease Diagnosis and Management Guideline. *Genet Med* 2006; 8(5):267-88.
5. Pellegrini N, Laforet P, Orlikowski D, Pellegrini M, Caillaud C, Eymard B, et al. Respiratory Insufficiency and Limb Muscle Weakness in Adults with Pompe Disease. *Eur Respir J* 2005; 26(6):1024-31.
6. Mellies U, Lofaso F. Pompe: A Neuromuscular Disease with Respiratory Muscle Involvement. *Respir Med* 2009; 103(4):477-84. doi: 10.1016/j.rmed.2008.12.009.
7. Mellies U, Dohna-Schwake C, Voit T. Respiratory Function Assessment and Intervention in Neuromuscular Disorders. *Curr Opin Neurol* 2005; 18(5):543-7.
8. Mellies U, Ragette R, Schwake C, Baethmann M, Voit T, Teschler H. Sleep-Disordered Breathing and Respiratory Failure in Acid Maltase Deficiency. *Neurology* 2001; 57(7):1290-5.
9. Berger KI, Chan Y, Rom WN, Oppenheimer BW, Goldring RM. Progression from Respiratory Dysfunction to Failure in Late-onset Pompe Disease. *Neuromuscul Disord* 2016;26(8):481-9. doi.org/10.1016/j.nmd.2016.05.018
10. Rezaitalab F, Frouhipour M, Sasannejad P. The Association of Headaches with Obstructive Sleep Apnea Syndrome Diagnose at the Sleep Laboratory of Ebn-e-Sina Hospital in Mashhad. *Medical Journal of Mashhad University of Medical Science* 2014; 56:323-329. [Text in Persian]
11. Headache Classification Committee of the International Headache Society (IHS). The International Classification of Headache Disorders, 3rd edition (beta version).

- Cephalalgia 2013; 33(9):629-808. DOI: 10.1177/0333102413485658
12. Preisler N, Lukacs Z, Vinge L, Madsen KL, Husu E, Hansen RS, et al. Late-Onset Pompe Disease is Prevalent in Unclassified Limb-Girdle muscular dystrophies. *Mol Genet Metab* 2013; 110(3):287-9. doi: 10.1016/j.ymgme.2013.08.005.
  13. Nazari F, Sinaei F, Nilipour Y, Fatehi F, Streubel B, Ashrafi MR, et al. Late-Onset Pompe Disease In Iran, A Clinical and Genetic Report. *Muscle Nerve* 2016; doi: 10.1002/mus.25413.
  14. Chu YP, Sheng B, Lau KK, Chan HF, Kam GY, Lee HH, et al. Clinical Manifestation of Late Onset Pompe Disease Patients in Hong Kong. *Neuromuscul Disord* 2016; 26(12):873-879. doi: 10.1016/j.nmd.2016.09.004.
  15. Hagemans ML, Hop WJ, Van Doorn PA, Reuser AJ, Van der Ploeg AT. Course of Disability and Respiratory Function in Untreated Late Onset Pompe Disease. *Neurology* 2006; 66(4):581-3.
  16. Boentert M, Dräger B, Glatz C, Young P. Sleep-Disordered Breathing and Effects of Noninvasive Ventilation in Patients with Late-Onset Pompe Disease. *J Clin Sleep Med* 2016;12(12):1623-1632. doi: 10.5664/jcsm.6346.
  17. Schoser B, Stewart A, Kanters S, Hamed A, Jansen J, Chan K, et al. Survival and Long-Term Outcomes in Late-Onset Pompe Disease Following Glucosidase Alfa Treatment: A Systematic Review and Meta-Analysis. *J Neurol* 2017; 264(4):621-630. doi: 10.1007/s00415-016-8219-8.
  18. The MENA Pompe Working Group. Diagnosis and Treatment of Late-Onset Pompe Disease in the Middle East and North Africa Region: Consensus Recommendations From an Expert Group. *BMC Neurology* 2015; 15:205. DOI: 10.1186/s12883-015-0412-3