



Research Paper: The Effects of Photobiomodulation on Shoulder Pain, Muscle Thickness, and Function in Subjects With Adhesive Capsulitis



Kamran Ezzati¹, Amir Salari^{2*}, Saemeh Khani³, Arash Aris²

1. Neuroscience Research Center, Poorsina Hospital, School of Medicine, Guilan University of Medical Sciences, Rasht, Iran.

2. Department of Orthopedic, Orthopedic Research Center, Poorsina Hospital, Guilan University of Medical Sciences, Rasht, Iran.

3. Department of Physical Therapy, Poorsina Hospital, School of Medicine, Guilan University of Medical Sciences, Rasht, Iran.

Use your device to scan and read the article online



Citation Ezzat K, Salari A, Khani S, Aris A. The Effects of Photobiomodulation on Shoulder Pain, Muscle Thickness, and Function in Subjects With Adhesive Capsulitis. Caspian J Neurol Sci. 2022; 8(2):90-97. <https://doi.org/10.32598/CJNS.8.29.1>

Running Title Photobiomodulation in Adhesive Capsulitis

doi <https://doi.org/10.32598/CJNS.8.29.1>



© 2018 The Authors. This is an open access article under the CC-BY-NC license.

ABSTRACT

Background: Adhesive capsulitis or frozen shoulder is among the most prevalent causes of pain and disability in individuals.

Objectives: We aimed to evaluate the effect of Photobiomodulation (PBM) on pain, range of motion, and thickness and function of supraspinatus muscle in patients with adhesive capsulitis.

Materials & Methods: Overall, 52 subjects (n=26/group) with adhesive capsulitis referring to Poorsina Hospital, physiotherapy ward, Rasht City, Iran, in 2019 participated in this study. They were randomly assigned to 2 groups of control or routine physical therapy and PBM group. The variables were pain (Visual Analogue Scale, VAS), range of motion (goniometer), the supraspinatus muscle thickness in rest and contraction, and muscle function (ultrasonography). The outcomes were examined before, after 5 and 10 sessions, and at a 1-month follow-up.

Results: There were no significant differences between the two groups regarding the demographic characteristics and studied variables. The interaction of group and time (2×4) was significant for pain (P=0.02). Finally, the Bonferroni post hoc test data indicated the pain reduction in the PBM group was higher than the control group at the follow-up (P=0.03). The mixed two-factor analysis of variance indicated that the interaction of the group and time of shoulder abduction (P=0.6), shoulder external rotation (P=0.46), supraspinatus muscle thickness, rest (P=0.31), supraspinatus muscle thickness, contraction (P=0.11), and rest-contraction (P=0.66) were not significant.

Conclusion: The PBM revealed greater analgesic effects than routine physical therapy in the short term and one-month follow-up. However, the effects on a range of motion and muscle thickness and function were insignificant.

Keywords: Adhesives, Shoulder pain, Physical therapy, Ultrasonography

Article info:

Received: 09 Dec 2021

First Revision: 25 Dec 2021

Accepted: 10 Feb 2022

Published: 01 April 2022

* Corresponding Author:

Amir Salari

Address: Department of Orthopedic, Orthopedic Research Center, Poorsina Hospital, Guilan University of Medical Sciences, Rasht, Iran.

Tel: +98 (912) 8170934, **Fax:** +98 (13) 33339842

E-mail: dr.amirsalari58@yahoo.com

Highlights

- Photobiomodulation showed short-term and long-term analgesic effects in patients with adhesive capsulitis.
- Compared with routine physical therapy, photobiomodulation did not reveal significant changes in the range of motion and muscle thickness and function in patients with adhesive capsulitis.

Introduction

Adhesive capsulitis or frozen shoulder is among the most common causes of pain and disability in people whose prevalence is estimated at 2-5% [1-3]. An important feature of this disease is pain and limited movement in the shoulder [4]. Numerous studies have examined the pathophysiology of adhesive capsulitis and the best modality and treatment method for it [5-7]. There are numerous interventions for adhesive capsulitis, including drug therapies [8], arthroscopic release [9], intra-articular injections [10, 11], suprascapular nerve block [12], manipulation under anesthesia [13], and physical therapy and exercise therapy [14-17].

Physical therapy interventions have received more attention due to their non-invasive nature [16, 17]. Common interventions in the physical therapy of patients with adhesive capsulitis include manual techniques, exercise therapy, and physical modalities generally used to reduce pain and increase range of motion [16]. Among the physical modalities, laser therapy known as Photobiomodulation (PBM) may increase metabolic capacity, ATP production, and cellular energy level and lead to cell function and repair [18, 19]. PBM uses non-ionizing light and is a nonthermal process that changes molecular functions due to dose-response effects [19].

The shoulder's rotator cuff muscles play the most crucial role in regulating dynamic stability and arthrokinematics [20]. The supraspinatus muscle has a more influential role and is the most biomechanically active shoulder muscle [21]. On the other hand, poor blood supply is more prone to degeneration than other muscles. Studies indicated that supraspinatus muscle injury directly alters the arthrokinematics of the shoulder joint and, depending on the severity of the injury, may completely impair joint movement [22, 23]. Therefore, the evaluation and treatment of structural and functional defects of this muscle are critical in completing the treatment process of adhesive capsulitis [24].

Various studies use different tools to measure the thickness of soft tissues, including magnetic resonance imaging, computed tomography scans, and ultrasonography [25]. In the present study, measuring muscle function using ultrasonography after treatment methods is a new perspective that previous studies have not developed [26].

There is no study examining the thickness of the supraspinatus muscle, as the most effective shoulder muscle in the occurrence of adhesive capsulitis has been measured by ultrasound [27]. Therefore, this study aimed to evaluate the effect of PBM on pain, Range of Motion (ROM), and thickness of supraspinatus muscle in patients with adhesive capsulitis.

Materials and Methods

This randomized controlled trial was performed from February 2019 to June 2020. Overall, 52 Subjects with shoulder adhesive capsulitis voluntarily participated in the present study. The inclusion criteria for the study included the age range of 18-50 years and diagnosing adhesive capsulitis as unilateral shoulder pain duration 3-9 months by an orthopedic surgeon [24]. The exclusion criteria were shoulder pain of less than 3-month, humeral fractures, cervical and shoulder surgeries, and bursitis. Moreover, the subjects with a history of physical therapy or any local injection within the last 3 months, psychological problems, and athletics were excluded. The study variables were pain, ROM, the supraspinatus muscle thickness in rest and contraction, the rest-thickness-contraction percentage.

The Visual Analogue Scale (VAS) assessed the intensity of pain. The patient's shoulder pain was recorded between 0 and 10 with the necessary explanation to the person, and they expressed their average pain over the past 24 hours [28]. Then, the height and weight of the subject were measured and recorded using a tape measure and scales. Besides, the Body Mass Index (BMI) was calculated by measuring Height (H) in centimeters and Weight (W) in kilograms. The range of abduction

and external rotation was also assessed by a goniometer [29]. Honda ultrasound machine (Honda electronics, HS 2000, Japan) and 5-10 MHz linear probe measured muscle thickness.

Shoulder ROM evaluations

The abduction was recorded using a goniometer. The subject was supine with the upper limbs next to the body and anatomical position. The patient moved his shoulder to abduct in the frontal plane. The goniometer was placed on bone landmarks; the fixed arm of the goniometer was placed parallel to the sternum. The axis of the goniometer was the acromion process, and its movable arm on the humerus was in the direction of the medial epicondyle [30, 31].

Furthermore, the range of external shoulder rotation was assessed by a goniometer. Thus, the study subject was in a supine position with the shoulder in 90-degree abduction, 90-degree elbow flexion, and forearm pronation. The fixed arm of the goniometer was perpendicular to the ground. The axis of the goniometer was on the ulceranon process, and its moving arm was on the forearm in the direction of the ulnar styloid process [31].

Ultrasound measurements were obtained while the study subject was sitting using the Honda ultrasound device and linear probe (5-10 MHz, HS, Japan) on the supraspinatus muscle. The shoulder was neutral (hanging next to the body), and the elbow was fully extended. Initially, the scapula was palpated, and a line was drawn along the spine of the scapula. The acromion and coracoid processes were also palpated, and a line was drawn between them. Another line is drawn along the length of the acromion. The probe was placed parallel to the spine of the scapula, and the scapular notch was identified. The probe was then rotated parallel to the line between the acromion and the coracoid process at the scapular notch, with the scapular notch centered. When the cross-section of the supraspinatus muscle was detectable, the closest distance between the center of the acromion-coracoid line and the outer edge of the probe was measured [30]. The upper and lower margins of the supraspinatus muscle were recorded as muscle thickness in the resting position of the upper limb on the side of the body and 60 degrees of scaption. The reliability of these measurements was reported previously [30]. All evaluation methods were recorded before, after 5 and 10 sessions, and a 1-month follow-up.

Intervention

The treatments of the control group consisted of the following:

1) Infrared (IR) lamp for 20 minutes: The IR lamp was placed at a distance of 50 cm from the person's shoulder and turned on. The patient also felt a mild heat.

2) Transcutaneous Electrical Nerve Stimulation (TENS) brief type for 20 minutes: In this method, 4 electrodes of the TENS were used on both sides of the affected shoulder. The frequency used varied between 3 and 120 Hz, and the patient felt an electric current to the point of tolerance with muscle tremor.

3) Ultrasound: The 1 MHz probe was used for 5 minutes on the anterior shoulder. The intensity was 0.8 w/cm², and the duty cycle was 20%.

4) Shoulder strengthening exercises: including 5 exercises, were performed twice daily from the third to the tenth session [17, 24, 32].

The treatment in the control group is a routine physical therapy treatment for patients with frozen shoulders. Since the same treatment is performed for the PBM group, this group can be considered a control group [33].

In the present study, a laser therapy device (CARSI, Brazil) with a wavelength of 905 nm, energy density 8J/cm², power 50 mW was radiated at 10 points of the shoulder, including 3 points in the anterior part of the capsule, 3 points in the posterior part of the capsule, two points on the root of the C5 nerve and two on the axilla was employed for the PBM group. The duration of irradiation for each point was 91s. The area was thoroughly cleaned with alcohol to minimize the skin's resistance. The therapist and the subject wore special glasses during treatment to prevent eye damage [34].

The Shapiro-Wilks test was used to evaluate the distribution of numerical variables. We used the Independent Samples t-test to compare variables, such as age, height, and weight among the patients before interventions. The Analysis of Variance (ANOVA) was used to evaluate the differences among groups, and the Bonferroni post hoc test was used to determine the mean differences between the study groups. The data analyses were performed in SPSS.

Table 1. Demographic information of the subjects with adhesive capsulitis in two groups

Variables	Mean±SD or No. (%)		P	
	Control Group	PBM Group		
Age (years)	50.0±6.42	50.81±8.32	0.69	
Weight (kg)	68.23±7.05	69.31±7.35	0.75	
Height (cm)	162.62±6.58	165.12±5.66	0.14	
Body Mass Index (kg/m ²)	25.98±5.16	24.18±4.16	0.10	
Pain duration (m)	4.48±2.92	5.19±2.72	0.36	
Gender	Female	6(23.1)	9(34.6)	0.07
	Male	20(76.9)	17(65.4)	
Side of pain	Right	18(69.2)	13(50.0)	0.05
	Left	8(30.8)	13(50.0)	



PBM: Photobiomodulation.

Results

In total, 52 subjects (26 per group) participated in this study. The demographic information of the patients with adhesive capsulitis is presented in Table 1. There were no significant differences between the two groups concerning demographic characteristics. Furthermore, other comparative variables didn't show significant differences between the research groups before treatment ($P>0.05$).

The control and PBM groups revealed a significant reduction in shoulder pain after the intervention. In the

control group, the initial Mean±SD value of pain (VAS) decreased from 7.23 ± 1.36 to 3.85 ± 3.25 at the final follow-up ($P<0.001$). Likewise, pain in the PBM group declined from 7.38 ± 1.29 to 2.35 ± 2.74 ($P<0.001$). The interaction of group and time (2×4) was significant for pain ($P=0.02$) (Figure 1).

Finally, the Bonferroni post hoc test results indicated the pain reduction in the PBM group was higher than the control group at follow-up ($P=0.02$) (Table 2).

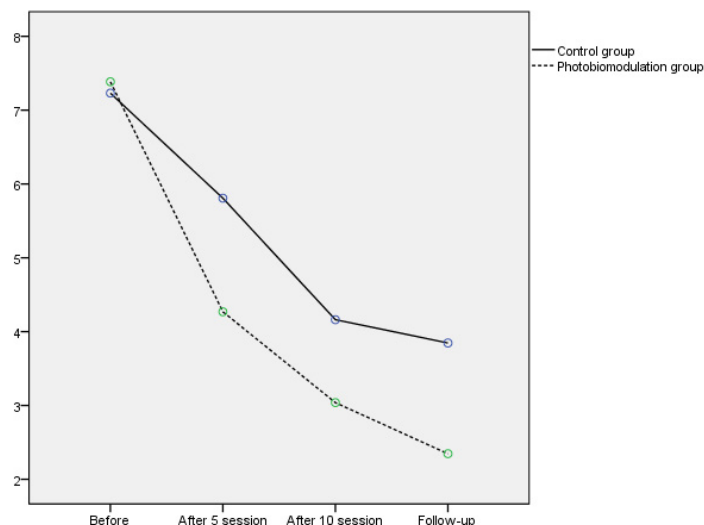


Figure 1. The changes of pain score between two groups before, after 5, 10 sessions, and 1 month follow up in patients with adhesive capsulitis

Table 2. Comparing the outcome measures before treatment and after 5, 10, sessions and 1-month follow-up in two studied groups

Variables		Mean±SD		P
		Control Group	PBM Group	
Pain	Initial	7.23±1.36	7.38±1.29	0.02
	After 5 session	5.81±2.36	4.27±2.29	
	After 10 session	4.16±2.7	3.04±2.52	
	1-month follow-up	3.85±3.25	2.74±1.14	
Shoulder abduction (deg)	Initial	76.81±16.48	74.42±19.25	0.6
	After 5 session	94.81±21.14	86.12±23.22	
	After 10 session	116.54±26.82	107.52±30.17	
	1-month follow-up	127.5±34.32	127.0±29.33	
Shoulder external rotation (deg)	Initial	37.88±18.77	32.5±15.7	0.46
	After 5 session	49.04±22.76	44.23±19.83	
	After 10 session	54.81±22.51	55.38±17.99	
	1-month follow-up	58.85±20.41	60.19±19.36	
Supraspinatus thickness (rest)	Initial	19.43±2.56	20.44±2.41	0.31
	After 5 session	18.75±2.41	19.9±2.03	
	After 10 session	18.71±2.25	20.42±2.09	
	1-month follow-up	18.2±2.14	20.07±2.38	
Supraspinatus thickness (contraction)	Initial	20.29±2.47	21.40±2.68	0.11
	After 5 session	19.76±2.08	21.05±2.28	
	After 10 session	19.59±2.18	21.17±2.36	
	1-month follow-up	19.9±2.47	21.65±2.57	
Supraspinatus thickness (% rest-contraction)	Initial	6.02±2.7	5.07±2.35	0.66
	After 5 session	6.66±2.37	5.81±4.53	
	After 10 session	4.91±4.85	5.52±2.74	
	1-month follow-up	9.36±5.19	8.24±7.83	

PBM: Photobiomodulation.



The mixed two-factor analysis of variance showed that the interaction of the group and time of shoulder abduction ($P=0.6$), shoulder external rotation ($P=0.46$), supraspinatus muscle thickness, rest ($P=0.31$), supraspinatus muscle thickness, contraction ($P=0.11$), and % rest-contraction ($P=0.66$) were not significant (Table 2).

Discussion

The aim of this study was to evaluate the effect of PBM on pain, shoulder ROM, and thickness and function of supraspinatus muscle in patients with frozen shoulders. The present study data highlighted that using PBM compared to routine physical therapy suggested a similar effect on the above variables. Both increased shoulder ROM and altered thickness and muscle function in patients with shoulder pain; however, compared between the two methods, neither was superior to the other. Nev-

ertheless, the effects of PBM were superior in pain reduction.

Some studies presented consent, and others indicated contrary findings with the present study [35-40]. Recently, Alfredo documented that combining laser therapy with exercises reduces pain intensity and improves shoulder function over 3 months in patients with subacromial impingement syndrome [41]. In the present study, the analgesic effects of laser therapy were more outstanding than the control group. The results of previous studies revealed that laser was also irradiated to the roots of the 5 cervical nerves; therefore, it revealed a more significant effect on reducing patients' pain than the control group. High-dose laser radiation to the nerve roots blocks the conduction of pain-receptors to higher centers and reduces patients' pain [19]. Therefore, choosing the correct dosage and appropriate points for

laser radiation are essential factors in reducing patients' pain perception [42].

Additionally, improved shoulder ROM and supraspinatus muscle function were significant in both groups after 1 month. These patients were in the freezing or painful phase of the disease, which pain being the most predominant symptom [24]. Therefore, reducing pain in these patients may have more prolonged effects, which were studied in the present study for up to one month [35, 36]. However, more prolonged analgesic effects of up to 6 months of laser therapy were indicated in previous studies [24]. Another noteworthy point is that reducing pain following laser radiation starts from the initial sessions and is more [34, 39]. However, improving ROM and muscle function takes more time. A longer follow-up time probably shows different results [23, 35].

The present study was the first to investigate the effects of PBM on muscle thickness and function using ultrasonography in patients with adhesive capsulitis. Improvement in muscle function and thickness did not differ significantly between the two groups after one month. One reason was the practice of the same exercise in both groups [36]. Furthermore, the location of the laser radiation was not on the target muscle; thus, it could not have more effects on its performance [43]. In future studies, laser radiation is suggested to be applied to the muscle to increase its thickness and function. However, other studies have supported these findings [44, 45].

The present study indicated that laser does not have more anti-inflammatory effects than other modalities, like ultrasound. Failure to consider the exact depth of the lesion and the use of low power laser and radiation on small and limited points (three points in front and three points behind the joint capsule with an area of 0.19 cm²) in the present study may be the reasons [42, 46]. The results of previous studies revealed that using a laser with higher power or radiation over a wider area and selecting more points may have better effects [36, 39, 42].

The main limitations of the present study were as follows: challenges in diagnosing adhesive capsulitis due to lack of objective instruments, the relatively small sample size for each group, the lack of long-term follow-up, and the lack of sham group.

Conclusion

The PBM indicated greater analgesic effects than routine physical therapy in the short term and one-month follow-up. However, the effects on ROM and muscle

thickness and function were insignificant in the short term and one-month follow-up.

Ethical Considerations

Compliance with ethical guidelines

All study procedures complied with the ethical guidelines of the Declaration of Helsinki 2013. All subjects filled in the consent forms (Ethics code: IR.GUMS.REC.1396.434) and were registered in the Iranian Clinical Trials Register (Code: IRCT20170516034003N2).

Funding

The present study was supported by the Deputy of Research and technology of Guilan University of Medical Sciences, Iran.

Authors contributions

Conceptualization: Kamran Ezzati, Saemeh Khani, Amir Salari, Arash Aris; Methodology: Kamran Ezzati, Saemeh Khani, Amir Salari, Arash Aris; Software: Saemeh Khani, Kamran Ezzati; Validation: Kamran Ezzati, Amir Salari, Arash Aris; Formal analysis: Kamran Ezzati, Saemeh Khani; Investigation: Kamran Ezzati, Saemeh Khani, Amir Salari, Arash Aris; Data curation: Kamran Ezzati, Saemeh Khani, Amir Salari; Writing – original draft preparation: Saemeh Khani, Kamran Ezzati, Amir Salari, Arash Aris; Writing – review & editing: Kamran Ezzati, Amir Salari, Saemeh Khani, Arash Aris; Visualization: Amir Salari, Arash Aris; Supervision: Kamran Ezzati; Project administration: Kamran Ezzati, Amir Salari, Saemeh Khani, Arash Aris; Funding Acquisition: Kamran Ezzati, Amir Salari.

Conflict of interest

The authors reported no conflict of interest.

Acknowledgements

The authors would like to thank the Deputy of Research and technology of Guilan University of Medical Sciences for supporting this research.

References

- [1] Rangan A, Brealey SD, Keding A, Corbacho B, Northgraves M, Kottam L, et al. Management of adults with primary frozen shoulder in secondary care (UK FROST): A multicentre, pragmatic, three-arm, superiority randomised clinical trial. *Lancet*. 2020; 396(10256):977-89. [DOI:10.1016/S0140-6736(20)31965-6]

- [2] Yeo SM, Lim JY, Do JG, Lim JY, In Lee J, Hwang JH. Effectiveness of interactive augmented reality-based telerehabilitation in patients with adhesive capsulitis: Protocol for a multi-center randomized controlled trial. *BMC Musculoskelet Disord.* 2021; 22(1):386. [DOI:10.1186/s12891-021-04261-1] [PMID] [PMCID]
- [3] Lowe CM, Barrett E, McCreesh K, De Búrca N, Lewis J. Clinical effectiveness of non-surgical interventions for primary frozen shoulder: A systematic review. *J Rehabil Med.* 2019; 51(8):539-56. [PMID]
- [4] Choi YH, Kim DH. Correlations between clinical features and MRI findings in early adhesive capsulitis of the shoulder: A retrospective observational study. *BMC Musculoskelet Disord.* 2020; 21(1):542. [DOI:10.1186/s12891-020-03569-8] [PMID] [PMCID]
- [5] Redler LH, Dennis ER. Treatment of adhesive capsulitis of the shoulder. *J Am Acad Orthop Surg.* 2019; 27(12):e544-54. [DOI:10.5435/JAOS-D-17-00606] [PMID]
- [6] Cho CH, Bae KC, Kim DH. Treatment strategy for frozen shoulder. *Clin Orthop Surg.* 2019; 11(3):249-57. [DOI:10.4055/cios.2019.11.3.249] [PMID] [PMCID]
- [7] Parashar A, Goni V, Neradi D, Guled U, Rangasamy K, Batra YK. Comparing three modalities of treatment for frozen shoulder: A prospective, double-blinded, randomized control trial. *Indian J Orthop.* 2020; 55(2):449-56. [DOI:10.1007/s43465-020-00201-8] [PMID] [PMCID]
- [8] Kitridis D, Tsikopoulos K, Bisbinas I, Papaioannidou P, Givissis P. Efficacy of pharmacological therapies for adhesive capsulitis of the shoulder: A systematic review and network meta-analysis. *Am J Sports Med.* 2019; 47(14):3552-60. [DOI:10.1177/0363546518823337] [PMID]
- [9] Boutefnouchet T, Jordan R, Bhabra G, Modi C, Saithna A. Comparison of outcomes following arthroscopic capsular release for idiopathic, diabetic and secondary shoulder adhesive capsulitis: A Systematic Review. *Orthop Traumatol Surg Res.* 2019; 105(5):839-46. [DOI:10.1016/j.otsr.2019.02.014] [PMID]
- [10] Shang X, Zhang Z, Pan X, Li J, Li Q. Intra-articular versus subacromial corticosteroid injection for the treatment of adhesive capsulitis: A meta-analysis and systematic review. *Biomed Res Int.* 2019; 2019:1274790. [DOI:10.1155/2019/1274790] [PMID] [PMCID]
- [11] Xiao RC, Walley KC, DeAngelis JP, Ramappa AJ. Corticosteroid injections for adhesive capsulitis: A review. *Clin J Sport Med.* 2017; 27(3):308-20. [DOI:10.1097/JSM.0000000000000358] [PMID]
- [12] Jung TW, Lee SY, Min SK, Lee SM, Yoo JC. Does combining a suprascapular nerve block with an intra-articular corticosteroid injection have an additive effect in the treatment of adhesive capsulitis? A comparison of functional outcomes after short-term and minimum 1-year follow-up. *Orthop J Sports Med.* 2019; 7(7):2325967119859277. [DOI:10.1177/2325967119859277] [PMID] [PMCID]
- [13] Kim DH, Song KS, Min BW, Bae KC, Lim YJ, Cho CH. Early clinical outcomes of manipulation under anesthesia for refractory adhesive capsulitis: Comparison with arthroscopic capsular release. *Clin Orthop Surg.* 2020; 12(2):217-23. [DOI:10.4055/cios19027] [PMID] [PMCID]
- [14] Tedla JS, Sangadala DR. Proprioceptive neuromuscular facilitation techniques in adhesive capsulitis: A systematic review and meta-analysis. *J Musculoskelet Neuronal Interact.* 2019; 19(4):482-91. [PMID]
- [15] Yip M, Francis AM, Roberts T, Rokito A, Zuckerman JD, Virk MS. Treatment of adhesive capsulitis of the shoulder: A critical analysis review. *JBJS Rev.* 2018; 6(6):e5. [DOI:10.2106/JBJS.RVW.17.00165] [PMID]
- [16] Alsubheen SA, Nazari G, Bobos P, MacDermid JC, Overend TJ, Faber K. Effectiveness of nonsurgical interventions for managing adhesive capsulitis in patients with diabetes: A systematic review. *Arch Phys Med Rehabil.* 2019; 100(2):350-65. [DOI:10.1016/j.apmr.2018.08.181] [PMID]
- [17] Nakandala P, Nanayakkara I, Wadugodapitiya S, Gawaramana I. The efficacy of physiotherapy interventions in the treatment of adhesive capsulitis: A systematic review. *J Back Musculoskelet Rehabil.* 2021; 34(2):195-205. [PMID]
- [18] Ezzati K, Fekrazad R, Raoufi Z. The effects of photobiomodulation therapy on post-surgical pain. *J Lasers Med Sci.* 2019; 10(2):79-85. [DOI:10.15171/jlms.2019.13] [PMID] [PMCID]
- [19] Shanks S, Leisman G. Perspective on broad-acting clinical physiological effects of photobiomodulation. *Adv Exp Med Biol.* 2018; 1096:41-52. [DOI:10.1007/5584_2018_188] [PMID]
- [20] Ferrer GDA. Understanding Key Biomechanical Factors that Influence Rotator Cuff Tear Propagation [PhD dissertation]. Pennsylvania: University of Pittsburgh; 2020. <https://www.proquest.com/openview/759a89856b50972fa9870dbb744dbbe0/1?pq-origsite=gscholar&cbl=18750&diss=y>
- [21] Gasbarro G, Bondow B, Debski R. Clinical anatomy and stabilizers of the glenohumeral joint. *Ann Jt.* 2017; 2(10):58. [DOI:10.21037/aoj.2017.10.03]
- [22] Yun SJ, Jin W, Cho NS, Ryu KN, Yoon YC, Cha JG, et al. Shear-wave and strain ultrasound elastography of the supraspinatus and infraspinatus tendons in patients with idiopathic adhesive capsulitis of the shoulder: A prospective case-control study. *Korean J Radiol.* 2019; 20(7):1176-85. [DOI:10.3348/kjr.2018.0918] [PMID] [PMCID]
- [23] Rawat P, Eapen C, Seema KP. Effect of rotator cuff strengthening as an adjunct to standard care in subjects with adhesive capsulitis: A randomized controlled trial. *J Hand Ther.* 2017; 30(3):235-41.e8. [DOI:10.1016/j.jht.2016.10.007] [PMID]
- [24] Giangarra CE. Clinical orthopaedic rehabilitation: A team approach. Amsterdam: Elsevier; 2017. https://www.google.com/books/edition/Clinical_Orthopaedic_Rehabilitation/NGkqvgAACAAJ?hl=en
- [25] Fields BKK, Skalski MR, Patel DB, White EA, Tomasian A, Gross JS, et al. Adhesive capsulitis: Review of imaging findings, pathophysiology, clinical presentation, and treatment options. *Skeletal Radiol.* 2019; 48(8):1171-84. [DOI:10.1007/s00256-018-3139-6] [PMID]
- [26] Kim YK, Choi ES, Kim KT, Yoon JR, Chae SH. Quantitative measurement of muscle atrophy and fat infiltration of the supraspinatus muscle using ultrasonography after arthroscopic rotator cuff repair. *Ann Rehabil Med.* 2018; 42(2):260-9. [DOI:10.5535/arm.2018.42.2.260] [PMID] [PMCID]
- [27] Collebrusco L, Lombardini R, Censi G. The Use of Ultrasound Images in Manual Therapy and Additionally in Assessment of Shoulder Impingement Syndrome. *Open J Therap Rehabil.* 2017; 5(02):53. [DOI:10.4236/ojtr.2017.52006]
- [28] Okuno Y, Iwamoto W, Matsumura N, Oguro S, Yasumoto T, Kaneko T, et al. Clinical outcomes of transcatheter arterial embolization for adhesive capsulitis resistant to con-

- servative treatment. *J Vasc Interv Radiol.* 2017; 28(2):161-7.e1. [DOI:10.1016/j.jvir.2016.09.028] [PMID]
- [29] Mullaney MJ, McHugh MP, Johnson CP, Tyler TF. Reliability of shoulder range of motion comparing a goniometer to a digital level. *Physiother Theory Pract.* 2010; 26(5):327-33. [PMID]
- [30] Yi TI, Han IS, Kim JS, Jin JR, Han JS. Reliability of the supraspinatus muscle thickness measurement by ultrasonography. *Ann Rehabil Med.* 2012; 36(4):488-95. [DOI:10.5535/arm.2012.36.4.488] [PMID] [PMCID]
- [31] Reese NB, Yates C, Bandy WD. Joint range of motion and muscle length testing. Amsterdam: Elsevier; 2015. https://www.google.com/books/edition/Joint_Range_of_Motion_and_Muscle_Length/2y_bnQEACAAJ?hl=en
- [32] Bélanger A. Therapeutic electrophysical agents: Evidence behind practice. Philadelphia: Wolters Kluwer/Lippincott Williams & Wilkins Health; 2014. https://www.google.com/books/edition/Therapeutic_Electrophysical_Agents/XcRInQEACAAJ?hl=en
- [33] Aggarwal H, Singh MP, Nahar P, Mathur H, Gv S. Efficacy of low-level laser therapy in treatment of recurrent aphthous ulcers-a sham controlled, split mouth follow up study. *J Clin Diagn Res.* 2014; 8(2):218-21. [DOI:10.7860/JCDR/2014/7639.4064] [PMID] [PMCID]
- [34] Stergioulas A. Low-power laser treatment in patients with frozen shoulder: Preliminary results. *Photomed Laser Surg.* 2008; 26(2):99-105. [DOI:10.1089/pho.2007.2138] [PMID]
- [35] Jeon CB, Choi SJ, Oh HJ, Jeong MG, Lee KS. The effects of high intensity laser therapy on pain and function of patients with frozen shoulder. *J Korean Phy Ther.* 2017; 29(4):207-10. [DOI:10.18857/jkpt.2017.29.4.207]
- [36] Zaki Z, Ravanbod R, Schmitz M, Abbasi K. Comparison of low level and high power laser combined with kinesiology taping on shoulder function and musculoskeletal sonography parameters in subacromial impingement syndrome: A Randomized placebo-controlled trial. *Physiother Theory Pract.* 2021; 1-12. [PMID]
- [37] Ökmen BM, Ökmen K. Comparison of photobiomodulation therapy and suprascapular nerve-pulsed radiofrequency in chronic shoulder pain: A randomized controlled, single-blind, clinical trial. *Lasers Med Sci.* 2017; 32(8):1719-26. [DOI:10.1007/s10103-017-2237-3] [PMID]
- [38] Silverman RG, Comey A, Sammons T. Effects of a single treatment with two nonthermal laser wavelengths on chronic neck and shoulder pain. *Med Devices (Auckl).* 2019; 12:319-25. [DOI:10.2147/MDER.S218649] [PMID] [PMCID]
- [39] Ezzati K, Laakso EL, Salari A, Hasannejad A, Fekrazad R, Aris A. The beneficial effects of high-intensity laser therapy and co-interventions on musculoskeletal pain management: A systematic review. *J Lasers Med Sci.* 2020; 11(1):81-90. [DOI:10.15171/jlms.2020.14] [PMID] [PMCID]
- [40] Tomazoni SS, Almeida MO, Bjordal JM, Stausholm MB, Machado CDSM, Leal-Junior ECP, et al. Photobiomodulation therapy does not decrease pain and disability in people with non-specific low back pain: A systematic review. *J Physiother.* 2020; 66(3):155-65. [DOI:10.1016/j.jphys.2020.06.010] [PMID]
- [41] Alfredo PP, Bjordal JM, Junior WS, Marques AP, Casarotto RA. Efficacy of low-level laser therapy combined with exercise for subacromial impingement syndrome: A randomised controlled trial. *Clin Rehabil.* 2021; 35(6):851-60. [DOI:10.1177/0269215520980984] [PMID]
- [42] Gendron DJ, Hamblin MR. Applications of photobiomodulation therapy to musculoskeletal disorders and osteoarthritis with particular relevance to Canada. *Photobiomodul Photomed Laser Surg.* 2019; 37(7):408-20. [DOI:10.1089/photob.2018.4597] [PMID] [PMCID]
- [43] da Cunha RA, Pinfieldi CE, de Castro Pochini A, Cohen M. Photobiomodulation therapy and NMES improve muscle strength and jumping performance in young volleyball athletes: A randomized controlled trial study in Brazil. *Lasers Med Sci.* 2020; 35(3):621-31. [DOI:10.1007/s10103-019-02858-6] [PMID]
- [44] de Paula Gomes CAF, Leal-Junior ECP, Dibai-Filho AV, de Oliveira AR, Bley AS, Biasotto-Gonzalez DA, et al. Incorporation of photobiomodulation therapy into a therapeutic exercise program for knee osteoarthritis: A placebo-controlled, randomized, clinical trial. *Lasers Surg Med.* 2018; 50(8):819-28. [DOI:10.1002/lsm.22939] [PMID]
- [45] Pinto HD, Vanin AA, Miranda EF, Tomazoni SS, Johnson DS, Albuquerque-Pontes GM, et al. Photobiomodulation therapy improves performance and accelerates recovery of high-level rugby players in field test: A randomized, crossover, double-blind, placebo-controlled clinical study. *J Strength Cond Res.* 2016; 30(12):3329-38. [DOI:10.1519/JSC.0000000000001439] [PMID]
- [46] Kim SH, Kim YH, Lee HR, Choi YE. Short-term effects of high-intensity laser therapy on frozen shoulder: A prospective randomized control study. *Man Ther.* 2015; 20(6):751-7. [DOI:10.1016/j.math.2015.02.009] [PMID]