



## The Utility of Diffusion Weighted Magnetic Resonance Imaging in Detection of the Origin of the Brain Solid Metastatic Tumors

Shabani Arash (MSc)<sup>1</sup>, Faeghi Fariborz (PhD)<sup>2\*</sup>, Rostamzadeh Ayoob (MSc)<sup>3</sup>, Jalal-Shokouhi Jalal (MD)<sup>4</sup>

### ARTICLE INFO

**Article type:**  
Original Article

**Article history:**  
Received: 1 July 2015  
Accepted: 13 August 2015  
Available online: 6 October 2015  
CJNS 2015; 1 (3): 19-26

1. Medical Imaging Physicist, Department of Radiology Technology, Faculty of Allied Medical Sciences, Shahid Beheshti University of Medical Sciences, Tehran, Iran
2. Medical Physics, Assistant Professor of Medical Imaging, Department of Radiology Technology, Faculty of Allied Medical Sciences, Shahid Beheshti University of Medical Sciences, Tehran, Iran
3. Neuroscientist, Department of Anatomical Sciences, Faculty of Medicine, Shahrekord University of Medical Sciences, Shahrekord, Iran
4. Radiologist, Iranian Society of Radiology, Head of Central Committee, Shahid Beheshti University of Medical Sciences, Tehran, Iran

**\*Corresponding author:**  
Radiology Technology  
Department, Faculty of Allied  
Medical Sciences, Shahid Beheshti  
University of Medical Sciences,  
Tehran, Iran

Email: f\_faeghi@sbmu.ac.ir

### ABSTRACT

**Background:** Early diagnosis of brain tumors has significant effect on the treatment process. Brain metastatic tumors are usually diagnosed following the neurological symptoms in patients or incidentally after Computerized Tomography (CT) scan and Magnetic Resonance Imaging (MRI) requests of the brain.

**Objectives:** Implementation of a new method for being informed about the origin of brain tumors by using MRI before surgery.

**Materials and Methods:** In this study, 25 patients with brain metastatic tumors were randomly selected and imaged with T2Weighted multi echo sequences and GRE EPI (DWI) in addition to taking routine sequence of brain. Software output such as variables including signal intensity, Apparent Diffusion Coefficient (ADC) value. In order to analyze the data and correlations between variables in this study, statistical t-test method and Graph pad prism software: version 5.4 has been used.  $p < 0.05$  was considered as the level of significance.

**Results:** Significant difference between ADC values at the center of metastatic tumors with different origin was found. ADC value of  $0.5613 \pm 0.02580 (\times 10^{-3} \text{ mm}^2/\text{s})$  indicates brain metastatic tumors with lung origin, ADC value of  $1.009 \pm 0.03820 (\times 10^{-3} \text{ mm}^2/\text{s})$  tumors with liver and breast origin, and ADC value of  $1.556 \pm 0.03500 (\times 10^{-3} \text{ mm}^2/\text{s})$  tumors with colon and prostate origin.

**Conclusion:** According to our results, DWI MRI as an imaging biomarker can determine the origin of the brain metastatic tumors, so that we can help patients and physicians in terms of time, financial and choice of the best treatment method.

**Key Words:** Brain; Magnetic Resonance Imaging

*Copyright © 2015 Caspian Journal of Neurological Sciences. All rights reserved.*

➤ **Please cite this paper as:**

Shabani A, Faeghi F, Rostamzadeh A, Jalal-Shokouhi J. The Utility of Diffusion Weighted Magnetic Resonance Imaging in Detection of the Origin of the Brain Solid Metastatic Tumors. Caspian J Neurol Sci 2015; 1(3):19-26.

### Introduction

The incidence of Central Nervous System (CNS) metastasis has been estimated to be approximately 3.8 per 10,000 persons annually (1). Metastasis is a process in which malignant cells are broken

and separated from a primary tumor, entered to the bloodstream or the lymphatic system, and disseminated in the body and different organs, and also known as an important factor in many causes of death in neoplastic

malignant lesions. Cancer in the breast, lungs and ovaries and the other organ can cause metastatic lesions in the brain (2). Approximately 10-20% of brain metastatic tumors are single, and the others are multiple. Breast and kidney cancer often causes single metastasis and cancer of the lung, and melanoma (skin cancer) causes multiple metastases in the brain area. Among all the primary tumors that cause metastasis in the brain, small cell carcinoma of the lung has the shortest period of time from diagnosis of the primary cancer to the involvement of brain area (3 months) and also the shortest period of time from metastasis to death (3 months) (3). Lung cancer is the most common cause of brain metastasis in men and women. Metastatic lesions of the brain are often diagnosed before, during or shortly after primary lung tumors (average of 6 to 9 months). Breast cancer is the second most common cause of metastasis in women and metastasis occurs a few years (average 2 to 2.5 years) after primary breast cancer and most often in young ages before menopause (3,4). Metastatic melanoma is the second most common cause of metastasis in men usually occurs some years after the initial melanomas; the incidence of metastatic melanoma is high when the blood vessels tend to be bleeding. Colon cancer is the third most common cause of brain metastasis in men and women that occurs short years after the primary tumor (3,5). Kidney cancer can cause lesions in the brain in the years shortly after the tumor, and this metastatic tumor often contains blood vessels (3,4). Diffusion Weighted Imaging (DWI) can early show many abnormalities in the central nervous system including metastatic tumors and also the minor changes of brain areas that are not visible on conventional imaging (6-9). In

addition, DWI can reveal microstructure of tissues on the basis, giving information about random movement of water molecules, which is restricted in some directions due to tissue damages (4,5,7). Regarding to the fact that metastatic tumors have different origins, determining their origin is one of the important and valuable points to diagnose and treat the patients. The selection of treatment methods such as radiation, chemotherapy and surgery is dependent on this valuable technical information achieved by imaging or other methods (7,10). Regarding to the complexities of this imaging method and lack of sufficient knowledge among the specialized physicians and imaging centers about its extensive applications including the investigation of metastatic tumors origin and also the response to treatment before and after treatment methods, it is essential to conduct further studies in this field (9-11). An inverse relationship between cellular origin and ADC parameter in previous studies increases the likelihood of ADC to be useful in determining the origin of the tumors. Therefore, regarding to the evidence, the main purpose of this study was to investigate the origin of brain solid metastatic tumors using diffusion and conventional MRI parameters.

### **Materials and Methods**

The study was performed from 2012 to 2014 on 25 patients with brain metastatic tumor referring to an academic hospital affiliated to Shahid Beheshti University of Medical Sciences, Tehran, Iran. This project in the Ethics Committee of Shahid Beheshti University of Medical Science was adopted. Patients' participation in the project was voluntary, and the study method and objectives were explained to all the patients

and written informed consent was received from them.

Patients, who have to be under surgery, radiotherapy or chemotherapy based on the diagnosis of a specialist, were subjected to MRI test with predetermined and optimized sequences in a few days before, in order to determine the origin of metastatic tumors. In this study, only intra-axial tumors were quantitatively analyzed. MRI experiments were performed by MRI 1.5 Tesla (Siemens

Avanto model, Germany). For MRI tests of the brain area, the brain coil quadrature was used, and to prevent random movements of the patient, special holder pads were used. Using MRI software, an initial analysis of the images, and the final analysis was performed by SPIN software. Firstly, MRI tests were performed on the patients with brain tumors, which include routine sequences (Table 1) and the desired sequences of this study, the DWI (Table 2).

**Table 1.** Parameters of routine sequences performed before given protocols

Parameter /Sequence	Plane	TR(ms)	TE(ms)	NEX	Matrix Size	FOV(cm)	RFOV	Slice thickness(mm)	Number of Slices
T2W-FSE	Axial	3700	113	1	320×256	26	FOV 80 %	5	18
TIW-FSE	Axial	410	9	1	320×256	24	FOV 80 %	5	18
FLAIR	Axial	8000	90	2	320×256	24	FOV 80 %	5	18
T2W-FSE	Coronet	3700	113	1	320×256	23	FOV 80 %	4	20
TIW-FSE	Sagittal	410	9	1	320×256	24	FOV 90 %	4	16

**Table 2.** Parameters of DWI and T2W sequences

Parameter /Sequence	Plane	TR(ms)	TE(ms)	NEX	Matrix Size	FOV (cm)	RFOV	Slice thickness(mm)	Number of Slices
GRE-EPI (DWI)	Axial	3100	113	4	128×128	26	FOV 100 %	5	18
T2W Multi Echo	Axial	3000	352-22	1	320×256	24	FOV 80 %	4	8

Next, images were processed. Initial processing of images was performed by MRI device. Then, the processed raw images were entered to SPIN software and the final processing and analysis was performed on images in SPIN software. Finally, the outputs of SPIN software were analyzed in comparison with the results of sampling reported by pathologist. After importing the whole image of a cut in Mean Curve window, we selected all the images and draw one or more Region of Interest (ROI) on one or more images with the best contrast to show the tumor. After drawing ROI and measuring signal intensity, images with JPG and DICOM format were saved. There was no need to draw a curve about diffusion and

ADC images; and it would be done only by drawing one or more ROI on the images with better contrast of tumor. The patient was placed on the bed as supine, then his head was placed in eight channels coil for imaging the brain, and then some routine sequences of brain imaging including axial images T2 Weighted-TSE with parameters TR/TE: 5600/98 millisecond, slice thickness: 5mm and axial Fluid-Attenuated Inversion Recovery (FLAIR) with parameters TR/TE: 10000/103 millisecond, slice thickness: 5mm and V3-D T2 weighted with uniform matrix, and slice thickness: 1mm and Field of View (FOV): 250\*250mm were performed, and then images of DWI, DWI with multi directional diffusion weighted echo planar

sequence are prepared in accordance with the following parameters: *b-value* 1000: TR/TE: 8000/80 millisecond, number of slices: 60, non-linear gradient direction. Images were assessed by the radiologist and MRI scanning physicist, then the intensity of the signal obtained through SPIN software were analyzed with the results from pathology (primary tumor center and tumor type) previously specified by pathologist. Finally, neurosurgical treatment design was investigated to determine the efficacy of this imaging method in the preoperative evaluation of the tumors. After completion of the brain routine sequences, required sequences for research were conducted. First, T1 Weighted and T2 Weighted Multi echo sequence and then, sequence of Diffusion-Weighted Imaging (DWI) or Gradient-Echo - Echo-Planar Imaging (GRE EPI) was performed (Tables 1 and 2).

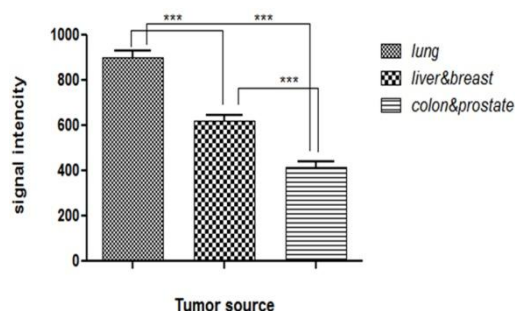
In order to analyze the data and correlations between variables in this study, statistical t-test method and Graph pad prism software: version 5.4 has been used. For convenience, the analysis of signal intensity and ADC data were analyzed separately.

## Results

### Software Outputs (signal intensity)

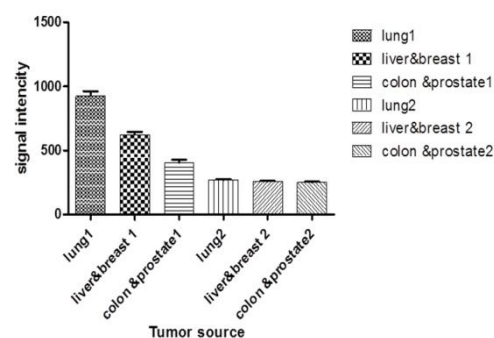
In analyzing the data for signal intensity using the software graph pad prism and t-test, there has been observed a significant relationship between the signal intensity of the tumor center and around it and also the signal intensity of metastatic tumors with origin of the lung, liver- breast and colon-prostate. To separate the signal intensity of the tumor center from the area around the tumor, the numbers 1 and 2 has been used respectively. For example, lung1 represents the signal intensity of the center of metastatic

tumors with lung origin, and lung 2 origins represent the signal intensity around the metastatic tumors with lung origin. Diagram 1 presents the figure corresponded to the signal intensity of metastatic tumors originating from lung, liver-breast and colon-prostate. Stars indicate semantic relationship between data.



**Diagram 1:** Signal intensity of metastatic tumors originating from lung, colon-prostate and breast-liver \*\*\*  $p < 0.001$ .

Diagram 2 shows the curve of signal intensity at the center area around the tumor in different groups at once.



**Diagram 2:** Signal intensity at the tumor center and the area around the tumor in different groups (lung1 represents the signal intensity at the tumor center and lung 2 represents the signal intensity at the area around the tumor).

As it can be seen, there is no significant difference between signal intensity around the tumor in different groups and they are within a numerical range. But there is a significant difference between signal intensity in the center of tumor and the area around and also signal intensity at the center of tumor in different groups. Generally, signal intensity of

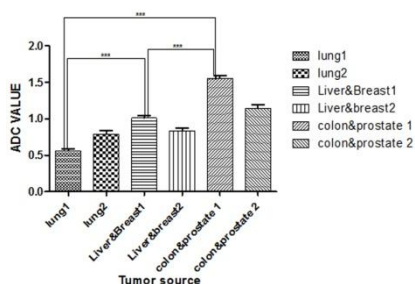
899.3±33.87 indicates brain metastatic tumors with lung origin, signal intensity of 621.3±24.53 tumors with liver and breast origin, and signal intensity of 416.1±23.51 tumors with colon and prostate origin (Table 3).

**Table 3.** The results of signal intensity data analysis

Tumor origin	Signal intensity at tumor center
Lung	899.3±33.87
Liver-Breast	621.3±24.53
Colon- Prostate	416.1±23.51

### Software outputs (ADC-VALUE)

In analyzing the data for ADC parameter using the software graph pad prism and t-test,  $p < 0.05$ , there has been no significant relationship between ADC value at the tumor center and around the tumor. The ADC values of metastatic tumors with lung, liver- breast and colon-prostate origin have been shown to have significant difference. Diagram 3 shows the figure corresponded to ADC of metastatic tumors originating from lung, liver-breast and colon-prostate. To separate ADC at the tumor center from the area around the tumor, the numbers 1 and 2 has been used respectively. Stars indicate significant relationship between data.



**Diagram 3:** ADC values at the tumor center and the area around the tumor in different groups (1 represents ADC values at the tumor center and 2 represents ADC values at the area around the tumor), \*\*\*  $p < 0.02$ .

As it can be seen, there is no significant difference between ADC values around the tumor in different groups and they are within a numerical range.

Generally, tumor center ADC value of  $0.5613 \pm 0.02580 (\times 10^{-3} \text{ mm/s})$  indicates brain

metastatic tumors with lung origin, ADC value of  $1.009 \pm 0.03820 (\times 10^{-3} \text{ mm/s})$  tumors with liver and breast origin, and ADC value of  $1.556 \pm 0.03500 (\times 10^{-3} \text{ mm/s})$  tumors with colon and prostate origin. Table 4 shows statistical analysis performed by prism.

**Table 4.** Results of statistical test performed using prism software.

Tumor origin	ADC values at the center of tumor ( $\times 10^{-3} \text{ mm/s}$ )
Lung	0.5613±0.02580
Liver-Breast	1.009±0.03820
Colon- Prostate	1.556±0.03500

### Discussion

Accordingly, in this study, brain intra-axial tumors were investigated by the help of this software and significant results were obtained. The results indicated that useful findings on the origin of a metastatic tumor can be achieved by the help of MRI, using some optimized sequences sensitive to the record of molecular diffusion, and also employing advanced software analysis. Also it opened new doors to answer the questions about the origin of a metastatic tumor that imaging and scanning of body organs are performed to answer them.

In this study, by using the capabilities of SPIN software and using two sequences sensitive to the change of content and water diffusion of a tissue, some features and variables were investigated among which relaxation time feature T2 and ADC are respectively obtained from the analysis of T2 Multi echo and DWI sequences (7,8). There is no significant difference between ADC values at the area around the tumor in different groups, and they are almost in a numerical range (9). Svolos P, *et al.* and Guo AC, *et al.* through diffusional experiments on patients with brain tumors concluded that the ADC may be helpful in the detection of astrocytes tumors malignity, although there are some



overlap between the ADC of astrocytoma tumor (grade II) and glioblastoma tumor. They also showed that astrocytoma with low-grade (grade II), has ADC value more than other tumors. And ADC is related to the tumor cellular origin both in astrocytes and in meningioma (11,12). This study suggested that low grade tumor has ADC value more than high grade tumors. The results of our research showed that metastatic tumors with lung origin have ADC lower than metastatic tumors with liver-breast origin, and metastatic tumors with lung liver-breast origin have ADC lower than metastatic tumors with colon-prostate origin (6,13,14). By the other words, metastatic tumors with lung origin generate tumors with more severity and damage in brain. As it was mentioned in the introduction, lung cancer is the most common cause of brain metastasis in men and women, and among all the primary tumors that cause metastasis in the brain, small cell lung carcinoma has the shortest period of time from diagnosis of the primary cancer to the involvement of brain area (3 months) and also the shortest period of time from metastasis to death (3 months). Berghoff and colleagues in 2013, through diffusional experiments on the patients with metastatic tumors and its relationship with survival times, concluded that metastatic tumors have a density greater, lower, or equal to brain tissue and in tumors with greater signal intensity in DW images have worse (shorter) survival time than other tumors (14). High signal intensity in DW images is dependent on the excessive discharge of interstitial reticulum which in this study the numerical values of ADC parameter and also the origin of the tumor and type of the tumor are not implied; but the results obtained in our studies indicate a particular connection between the origin of

the tumor and its type, and statistical results also confirm it (11).

In analyzing of ADC parameter there has been no significant relationship between ADC value at the tumor center and around the tumor and also no significant difference between ADC values around the tumor in different groups. But ADC values at the center of tumor in different groups of metastatic tumors with lung, liver-breast and colon-prostate origin have shown significant difference. It can be said in brief that, the more the tumor is malignant, the lower ADC it has. As it is observed in the curve related to the ADC parameter, all groups have higher ADC than around area, but metastatic tumor with lung origin has lower ADC than the area around which is probably due to the high mass effect of this tumor and its malignity (5,8,15). The studies performed on the sample by Chen L, *et al.* and also the researches performed on patients concluded that, the signal intensity in DW images indicates the histology of metastasis (9). It also showed that adenocarcinoma of well differentiated type have a tendency to create image with low signal intensity (hypo intense), while the small and large cell neuroendocrine carcinoma shows image with high signal intensity. In this study, signal has not been measured quantitatively, and one of the main deficiencies of the research is that, it is not clear signal intensity has been investigated in which sequence; because the sensitivity of sequence to the lesion can be increased by choosing different b-value in DW images and then obtain different signal intensity (14,16). Therefore, certain TE, TR and T2 Weighted sequences have been used in our studies to measure signal intensity. SPIN advanced software has been also used for quantitative measurements of signal intensity. The

interesting thing in signal intensity curve is that, malignant tumors have greater signal intensity. Tung GA, *et al.* through DW experiments on the patients with brain tumor showed that the limitation of water molecules diffusion is not specific to the patients with brain abscess, and it is observed in other patients with brain tumors (10). The researcher's experience also showed that rim-enhancing brain masses illustrate the increase in the signal intensity in diffusion images and decrease in the signal intensity in ADC Map. The signal intensity on DW sequences has been visually compared, while this signal intensity can be changed by varying the parameter. On the other hand, signal intensity on DW sequences is affected by diffusion phenomenon (the random movement of water molecules). But in the T2W sequence, signal intensity is affected both by diffusion phenomenon and T2 relaxation time (11,13,15). Thus, it is more accurate quantitatively. One of the issues that must be investigated further is that, ADC curve of the central tumor area with lung origin is lower than the area around. While in other groups, ADC value of central area is higher than the around and is graphically located at a higher level. Studies in this area suggest that metastatic tumors originating from lung damage most of blood-brain barrier and also create more cellular damage which in turn could lower the numerical value of ADC in this group of tumors (11,12,15,16). This type of tumor also causes mass effects and greater edema in the tumor center, which is one reason for the low ADC values.

## Conclusion

According to obtained results, we can identify the origin of brain metastatic tumors easily and prevent from doing additional MRI

and CT scan test from other parts of the body in order to determine the origin of the brain metastatic tumors and biopsy too, so that we can help patients and physicians in terms of time, financial and choice of the most appropriate therapy method.

## Acknowledgement

The study was supported by grants from the Research Council of the Shahid Beheshti University of Medical Sciences. Authors would like to thank the patient for participating in this study.

## Conflict of Interest

No conflict of interest.

## References

1. Louis DN, Ohgaki H, Wiestler OD, Cavenee WK, Burger PC, Jouvet A, et al. The 2007 WHO Classification of Tumours of the Central Nervous System. *Acta Neuropathol* 2007; 114(2): 97-109.
2. Brem S, Panatier JG. An Era of Rapid Advancement: Diagnosis and Treatment of Metastatic Brain Cancer. *Neurosurgery* 2005;57(5):S4-5.
3. Lu-Emerson C, Eichler AF. Brain Metastases. *Continuum (Minneapolis)* 2012;18(2):295-311.
4. Young GS. Advanced MRI of Adult Brain Tumors. *Neurol Clin* 2007;25(4):947-73.
5. Provenzale JM, Mukundan S, Barboriak DP. Diffusion-Weighted and Perfusion MR Imaging for Brain Tumor Characterization and Assessment of Treatment Response 1. *Radiology* 2006;239(3):632-49.
6. Nemeth A, Henson J, Mullins M, Gonzalez R, Schaefer P. Improved Detection of Skull Metastasis with Diffusion-Weighted MR Imaging. *AJNR Am J Neuroradiol* 2007;28(6):1088-92.
7. Mori S, Zhang J. Principles of Diffusion Tensor Imaging and Its Applications to Basic Neuroscience Research. *Neuron* 2006;51(5):527-39.

8. Bammer R. Basic Principles of Diffusion-Weighted Imaging. *Eur J Radiol* 2003;45(3):169-84.
9. Chen L, Liu M, Bao J, Xia Y, Zhang J, Zhang L, et al. The Correlation Between Apparent Diffusion Coefficient and Tumor Cellularity in Patients: a Meta-Analysis. *PLoS One* 2013;8(11):e79008.
10. Tung GA, Evangelista P, Rogg JM, Duncan JA 3rd. Diffusion-Weighted MR Imaging of Rim-Enhancing Brain Masses: Is Markedly Decreased Water Diffusion Specific for Brain Abscess? *AJR Am J Roentgenol* 2001;177(3):709-12.
11. Svolos P, Kousi E, Kapsalaki E, Theodorou K, Fezoulidis I, Kappas C, et al. The Role of Diffusion and Perfusion Weighted Imaging in the Differential Diagnosis of Cerebral Tumors: a Review and Future Perspectives. *Cancer Imaging* 2014;14:20.
12. Guo AC, Cummings TJ, Dash RC, Provenzale JM. Lymphomas and High-Grade Astrocytomas: Comparison of Water Diffusibility and Histologic Characteristics 1. *Radiology* 2002;224(1):177-83.
13. Cruz Júnior LC, Sorensen AG. Diffusion Tensor Magnetic Resonance Imaging of Brain Tumors. *Neurosurg Clin N Am* 2005;16(1):115-34.
14. Berghoff AS, Spanberger T, Ilhan-Mutlu A, Magerle M, Hutterer M, Woehrer A, et al. Preoperative Diffusion-Weighted Imaging of Single Brain Metastases Correlates with Patient Survival Times. *PloS one* 2013;8(2):e55464.
15. Stadnik TW, Chaskis C, Michotte A, Shabana WM, van Rompaey K, Luypaert R, et al. Diffusion-Weighted MR Imaging of Intracerebral Masses: Comparison with Conventional MR Imaging and Histologic Findings. *AJNR Am J Neuroradiol* 2001;22(5):969-76.
16. Okamoto K, Ito J, Ishikawa K, Sakai K, Tokiguchi S. Diffusion-Weighted Echo-Planar MR Imaging in Differential Diagnosis of Brain Tumors and Tumor-Like Conditions. *Eur Radiol* 2000;10(8):1342-50.