



The Findings of Transcranial Doppler Ultrasonography in Patients with Ischemic Stroke

Hosseiniyehzad Mozaffar (MD)¹, Roudbary Seyed-Ali (MD)^{2*}, Keshavarzi Iraj (MD)³, Hojjati Seyed-Mohammad-Masood⁴ (MD), Kazemnezhad-Leili Ehsan⁵ (PhD)

ARTICLE INFO

Article type:
Original Article

Article history:
Received: 17 June 2015
Accepted: 28 June 2015
Available online: 9 July 2015
CJNS 2015; 1 (2): 8-14

1. Department of Neurology, Poursina Hospital, Guilan University of Medical Sciences, Rasht, Iran
2. Neurologist, Associated Professor, Neurology Department of Poursina Hospital, Guilan University of Medical Sciences, Rasht, Iran
3. Resident of Neurology, Neurology Department of Poursina Hospital, Guilan University of Medical Sciences, Rasht, Iran
4. Department of Neurology, Babol University of Medical Sciences, Babol, Iran
5. Specialist of Biostatistics, Assistant Professor, Guilan Trauma Research Center, Guilan University of Medical Sciences, Rasht, Iran

***Corresponding author:**
Neurologist, Associated Professor, Neurology Department of Poursina Hospital, Guilan University of Medical Sciences, Rasht, Iran
Email: roudbary@gums.ac.ir

ABSTRACT

Background: Stroke is a multifactorial disorder, the most common cause being arterial occlusion. Transcranial Doppler Ultrasonography (TCD) is a common non-invasive method available for assessment the arterial blood flow of the brain.

Objective: Assessment the hemodynamic parameters of cerebral arteries, using TCD device in patients suffering ischemic stroke.

Materials and Methods: This descriptive cross-sectional study was conducted on patients with ischemic stroke in 2014 in Iran after being approved by ethics committee of Researches and Technology Vice-chancellorship of Guilan University of Medical Sciences. After obtaining informed consent, all patients underwent TCD. Demographic details and TCD findings were recorded. Data were analysed in SPSS software 21 using independent t-test, Chi-square, and Fisher's exact tests. The descriptive results were presented as mean \pm SD and frequency.

Results: A total of 102 patients (69 men and 33 women) with ischemic stroke and mean age of 63.72 ± 12.64 years participated in this study. Among 49.02% of patients at least one hemodynamic abnormality was diagnosed. Small Vessel Disease (SVD), extracranial stenosis (ECS) and intracranial stenosis (ICS) were found in 29.41%, 20.59% and 11.76% of patients respectively.

Abnormal Pulsatility Index (PI), Peak Systolic Velocity (PSV) and Mean Blood Flow Velocity (Vm) were reported in 32.25%, 20.59% and 9.8% of them respectively. A significant relationship was found between PSV parameter and also presence of ECS and gender ($p = 0.047$). Moreover, SVD and abnormal PI were found significantly related to age ($p = 0.002$).

Conclusion: TCD results showed almost half of the patients with ischemic stroke were found to have at least one hemodynamic abnormality.

Keywords: Stroke; Ischemia; Ultrasonography, Doppler, Transcranial; Cerebral Arteries

Copyright © 2015 Caspian Journal of Neurological Sciences. All rights reserved.

➤ **Please cite this paper as:**

Hosseiniyehzad M, Roudbary SA, Keshavarzi I, Hojjati SMM, Kazemnezhad-Leili E. The Findings of Transcranial Doppler Ultrasonography in Patients with Ischemic Stroke. Caspian J Neurol Sci 2015; 1(2):8-14.

Introduction

Worldwide the cerebral arterial disease is the second leading cause of mortality and disability

(1). Annually 3.29 persons per 1000 suffer stroke (2), which include intracranial hemorrhage and cerebral infarction (3).

Intracranial atherosclerosis results in cerebral arterial disease, which is responsible for 8% to 10% of ischemic strokes and increasing the risk of recurrent stroke by 15% in a year. Atherosclerotic lesions at the bifurcation site of common carotid artery, proximal part of internal carotid artery, and also proximal part of vertebral artery are known as the sources of embolus and consequently embolic stroke (4,5). Emboli originating from heart and also small vessels disease are two other important causes of ischemic stroke (6,7).

Currently, one of the medical challenges in treatment of ischemic stroke with thrombolytic agent to re-canalize cerebral arteries is its reversal effect as persistence or worsening of present neurological deficit or onset of new symptom. Ischemic stroke falls in a range from spontaneous recovery to worsening of arterial supply including spontaneous thrombolysis, arterial re-stenosis, spreading of the clots, and creating collateral arteries. Recognizing each of these events, if treatment is required, is possible through serial assessments (8). Digital subtraction angiography, Computed Tomography (CT) - Angiography and Magnetic Resonance Angiography (MRA) are useful methods for imaging of cerebrovascular anatomy and assessment of the collateral blood flow in acute stroke (9,10). Yet, in some centers and hospitals, these techniques may not be easily available immediately following admission of patients with acute stroke. More importantly, successive assessments using these methods may be hard or also impossible for patients due to escalating costs. Accordingly, using these techniques for careful monitoring of dynamic changes in cerebral vasculature maybe extremely difficult in practice (10,11). Transcranial Doppler Ultrasonography (TCD) is a non-invasive and reliable method

for assessment of blood flow in the basal intracerebral arteries, which adds physiological data to anatomic images. TCD can provide the easiest method for vascular assessment in clinical settings. TCD is considered as an appropriate option in terms of easy access for patient, patient comfort, sequential assessment, and even continuous monitoring, and occasional rapid and emergency assessment of patterns and status of cerebral blood flow. Considering emphasis on the need for determining prevalence of hemodynamic abnormalities in cerebral blood flow in various communities and regions (12), it was decided to study the prevalence of impaired hemodynamic parameters of cerebral arteries, as displayed by Spectral Waveform Doppler Ultrasonography in patients with ischemic stroke in an area in the North of Iran, in order to present numerous applications of cerebrovascular sonography in management of patients with cerebrovascular diseases.

Materials and Methods

This descriptive cross-sectional study was conducted on patients with ischemic stroke attending an academic hospital in Guilan Province in the North of Iran in 2014. Before enrolling the patients in the study an informed consent was obtained from the patients or their legal responsible. The proposal of this project was approved by the ethic committee of Researches and Technology Vice-chancellorship of Guilan University of Medical Science.

The diagnosis of stroke was made by one neurologist and Doppler ultrasonography by another expert one. Ischemic stroke was diagnosed according to usual clinical criteria and imaging. TCD device named Looki 2 TC

(Atys Medical Company, France) was used. Doppler ultrasound was performed in a period of 48 hours to one week after onset of symptoms. Patients with less than 48 hours since the onset of stroke, those in a seriously critical conditions, and also non-cooperative patients, and those with poor windows for observation of waveforms of cerebral arteries blood flow were excluded from the study.

Patients' demographic data obtained from their records, together with TCD data including Peak Systolic Velocity (PSV), Mean Blood Flow Velocity (Vm), and Pulsatility Index (PI) were recorded. PSV more than 125 cm/sec in internal carotid artery, and also Vm and PI of intracranial arteries outside normal range indicate impaired arterial hemodynamic parameters, which express a kind of abnormality. Normal

values of PI for intracranial arteries range from 0.85 to 1.1 (13). Normal ranges for Vm of intracranial arteries are represented in table 1 as follows:

Table 1 : Normal value of Mean Blood Flow Velocity (Vm in intracranial arteries

Artery	Mean Blood Flow Velocity (Vm) cm/sec
Middle Cerebral Artery (MCA)	60 ± 12
Anterior Cerebral Artery (ACA)	50 ± 12
Posterior Cerebral Artery (PCA)	40 ± 11
Internal Carotid Artery – Siphon Part	50 ± 12
Ophthalmic Artery (OA)	20 ± 10
Basilar Artery (BA)	40 ± 10
Vertebral Artery (VA)	40 ± 10

Also the following values of hemodynamic parameters presented in table 2 and table 3 were used for detection of serious stenosis of intra- and extra-cranial arteries (14).

Table 2 : Diagnostic criteria for stenosis of intracerebral arteries and its grading

Artery	Vm (cm/s)	Vm ≥ 50% stenosis (cm/s)	Vm ≥ 70% stenosis (cm/s)
M1-M2 MCA	≥ 80	≥ 100 (use 1:2 ratio)	≥ 128 (use 1:4 ratio)
A1 ACA	≥ 80	N/A	N/A
ICA siphon	≥ 70	≥ 90 (use 1:2 ratio)	≥ 128 (use 1:4 ratio)
PCA	≥ 50	N/A	N/A
BA	≥ 60	≥ 80 (use 1:2 ratio)	≥ 119 (use 1:4 ratio)
VA	≥ 50	≥ 80 (use 1:2 ratio)	≥ 119 (use 1:4 ratio)

Table 3: Diagnostic criteria for stenosis of extracranial carotid artery and its grading

Stenosis range (%)	ICA PSV (cm/s)	ICA/CCA ratio	ICA EDV (cm/s)	Plaque
Normal	< 125	< 2.0	< 40	None
< 50	< 125	< 2.0	< 40	< 50% diameter reduction
50-69	125-230	2.0-4.0	40-100	≥ 50% diameter reduction
70-near occlusion	> 230	> 4.0	> 100	≥ 50% diameter reduction
Near occlusion	May be low or undetectable	Variable	Variable	Significant, detectable lumen
Occlusion	Undetectable	Not applicable	Not applicable	Significant, no detectable lumen

After performing TCD for every participant, Vm and PI of each intracranial artery and PSV of internal carotid artery were determined. Given diagnostic criteria explained in previous sections, either patient did not have any pathological findings, or he/she had one or a few problems diagnosed, including extracranial stenosis (ECS), intracranial stenosis (ICS), or small vessel

disease (SVD). Rarely, they were putted in the miscellaneous group including arteriovenous malformation, anemia, and heart failure based on clinical assessment and other diagnostic methods.

Data obtained data were statistically analysed in SPSS software version 21 using independent t-test, Chi-square, and Fisher's

exact tests. Also the quantitative data were presented as Mean ± SD and frequency.

Results

A total of one hundred two patients (69 men and 33 women) with ischemic stroke and mean age of 63.72±12.64 years were enrolled in this study.

At least one hemodynamic abnormality was diagnosed in 49.02% of patients (n = 50). Accordingly, SVD was found in 29.41% of patients (n = 30) (high PI in all arteries), ECS in 20.59% (n = 21) (with moderate proximal stenosis of internal carotid), and ICS in 11.76% (n = 12) of them (ten cases had Vm greater than normal, and two cases had PI higher than normal in one intracranial artery) Miscellaneous condition was found in only one patient.

Abnormal PI, PSV and Vm were reported in 32.25% (n = 33), 20.59% (n = 21) and 9.8% (n = 10) of patients respectively. Overall, 37 patients had disorders in one parameter, 12 patients in two, and one patient in three parameters. Abnormal PI includes high PI in all arteries indicating SVD (29.41%, n = 30), high PI in one artery indicating stenosis in one of the intracranial arteries (2%, n = 2) and PI less than normal range in all arteries, indicating inadequate blood supply to brain (0.98%, n = 1). The latter case was reported involving by heart failure according to patient history. No case with PI less than normal range in one artery was observed. The Vm greater than normal range was found in 9.8% (n = 10) of patients with intracranial stenosis, and no cases of low Vm was reported in this study.

Of the twenty-one patients with ECS, seven subjects showed right internal carotid stenosis, seven cases, had left internal carotid

stenosis and the other cases demonstrated bilateral internal carotid stenosis. Thirteen cases were symptomatic in the side of the stenosis. Table 4 presents the prevalence of stenotic intracranial arteries as following:

Table 4: The prevalence of stenotic intracranial arteries

Artery	Number (%)
BA	2 (16.7%)
Left VA	3 (25.0%)
Left ICA - S	1 (8.3%)
Right MCA	3 (25.0%)
Right & Left VA	1 (8.3%)
Right ICA - S* & Left ICA-T**	1 (8.3%)
Right ICA-T & Left ICA - S	1 (8.3%)
Total	12 (100%)

*ICA-S : Siphon part-ICA

**ICA-T: Terminal part -ICA

According to Chi-square and Fisher's exact tests, among all hemodynamic parameters, gender distribution showed a significant relationship only with abnormal PSV, which was more prevalent in men (26.1% of men vs. 9.1% of women; *p* = 0.047). Also, ECS was also significantly more prevalent among men rather than women (*p* = 0.047). The other vascular abnormalities were prevalent in men as same as women (*p* > 0.05)

In assessment of age distribution, independent t-test showed a significant relationship between involvement of small vessels and age (mean age of 69.53±11.07 years in SVD patients vs. 61.29±12.53 years in non - SVD patients (*p* = 0.002) (Diagram 1), While no other relationship was found between other types of vascular involvement and aging

Similarly, PI abnormality was also significantly related to age, the mean age of patients with abnormal PI was 68.12±12.42 years and of whom with normal PI was estimated as 61.61±12.28 years (*p* = 0.014), but other hemodynamic parameters had no significant relationship with age.

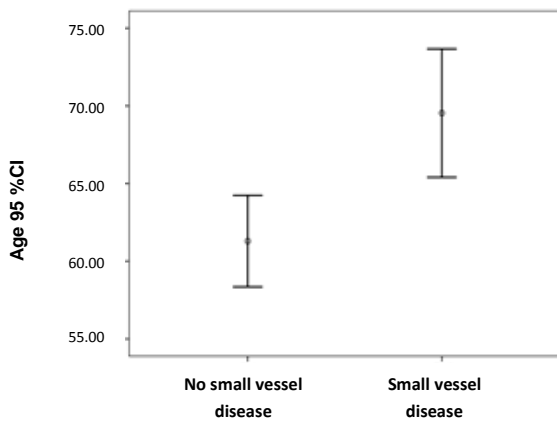


Diagram 1: The relationship between small vessels disease and age ($p = 0.002$).

Discussion

In TCD exam of predisposed subjects to stroke or stroke patients, abnormal increasing of the internal carotid artery PSV indicates serious atherosclerotic stenosis at bifurcation of common carotid artery or at the beginning of internal carotid artery. Abnormal increase in PI in all intracranial arteries in patients with normal consciousness indicates Small-Vessel Disease (SVD), while such an increase in only one artery suggests the downstream stenosis in that artery. Reduction of PI in one artery indicates upstream stenosis, and in all arteries suggests arteriovenous malformation or reduced blood supply to the brain. Abnormal increase in Vm of one artery denotes downstream stenosis, and abnormal decrease in Vm of one artery shows upstream stenosis (13,15).

The present study was conducted on one hundred two ischemic stroke patients with the following results: Of fifty patients that showed abnormal TCD results, 30 had SVD (high PI in all arteries). As discussed earlier, lacunar stroke is one of the most common types of stroke and comprises 20% of all stroke cases (7). Lyrer et al. also found 45% of their patients with this form of stroke; of

course they studied only the patients with arterial occlusion in the territory of Middle Cerebral Artery (MCA) (16). Whatever in the present study, SVD was found in 30% of patients; considering that ischemic lacunar infarction is associated with SVD (17,18). This result agrees with high PI in a large proportion of patients in the present study. The notable point of these results is that this type of stroke does not have so many presentations in some imaging methods such as brain Computed Tomography, while TCD produces an acceptable accuracy. In short, the most common pathologic finding in the present study patients using TCD was SVD. These patients also are at the risk of recurrence of ischemic stroke. This risk can be largely reduced by controlling hypertension and the other risk factors (7).

Twenty-one patients had ECS with moderate grade stenosis of proximal internal carotid artery (ICA), which meant filling of 50% to 69% of ICA cross section by atheroma. Of the 21 patients with ECS, 7 had right internal carotid stenosis, 7 had left internal carotid stenosis, and the next seven subjects had bilateral internal carotid stenosis, and in total, thirteen of them were symptomatic in the territory of involved artery and eight cases were asymptomatic. A study revealed that although carotid occlusion is the most common cause of TIA (19), it can cause ischemic stroke in 10% of cases (7). This figure is close to the present study finding that 20% of patients had serious atherosclerotic carotid stenosis, which was probably associated with symptoms in 13% of patients.

Twelve patients had ICS which 10 patients of them had high Vm in one artery, 2 had high PI in one intracranial artery, and one had low PI in all arteries, the latter one indicating

inadequate blood supply to the brain, which was due to heart failure. In the present study, no low VM cases were found. In their study on MCA, Lyrer et al. found significant differences between symptomatic and asymptomatic patients. Yet, in a 30-day assessment following stroke, 17 out of 22 patients had either high Vm (above 90 cm/sec), which showed stenosis of the MCA trunk (16). It is important to identify intracranial atherosclerosis (ICS), since, annually, 10% to 15% of these patients, like ECS, have recurrent stroke (7).

In the present study, gender distribution based on study parameters showed only higher PSV of internal carotid artery in men. Accordingly, ECS was also significantly more prevalent in men. Furthermore small vessel stenosis clearly more occurred among elders. In other words, SVD was significantly related to mean age of participants. This was also true about PI, so that those with abnormal PI were older. In fact, PI indicates the resistance of arterial endings, and its increasing suggests increased arterial resistance, for instance following atherosclerosis, lipohialinosis and vasoconstriction, and also its decrease is observed in vasodilatation following reduced perfusion, for instance in arterial aneurysms (20). Overall, it is clear that arterial atherosclerosis is age-dependent, and increases with aging (21,22). Considering that small vessel resistance occurs often in such diseases (17,18), increased PI according to age can be well-explained. SVD is caused by a kind of pathological change called lipohilinosi and also atherosclerosis and its risk factors include hypertension and age. These two changes can cause thrombosis and arterial occlusion. Of course embolus formation is the third occlusion mechanism in

SVD, which is responsible for about 20% of strokes (6,7).

Finally it must be concerned that the limitation of this study was its time-consuming process. This diagnostic method takes at least an hour for each patient. Some patients were found to have poor acoustic windows after spending a lot of time, and were excluded accordingly.

Conclusion

According to Spectral Waveform Doppler Ultrasonography results, half of the patients with ischemic stroke were found to have at least a kind of hemodynamic abnormality with etiology of stroke, so that secondary prevention was to be designed accordingly. Also as the only neuro-sonologic method, TCD can be considered as a screening tool for assessment of stroke patients.

Conflict of Interest

No Conflict of Interest

References

1. Woo J, Ho SC, Goggins W, Chau PH, Lo SV. Stroke Incidence and Mortality Trends in Hong Kong: Implications for Public Health Education Efforts and Health Resource Utilisation. *Hong Kong Med J* 2014;20(3 Suppl 3):24-9.
2. Koton S, Schneider AL, Rosamond WD, Shahar E, Sang Y, Gottesman RF, et al. Stroke Incidence and Mortality Trends in US Communities, 1987 to 2011. *Jama* 2014;312(3):259-68.
3. Gorter PM, Olijhoek JK, van der Graaf Y, Algra A, Rabelink TJ, Visseren FL, et al. Prevalence of the Metabolic Syndrome in Patients with Coronary Heart Disease, Cerebrovascular Disease, Peripheral Arterial Disease or Abdominal Aortic Aneurysm. *Atherosclerosis* 2004;173(2):363-9.
4. Stampfl S, Ringleb PA, Mohlenbruch M, Hametner C, Herweh C, Pham M, et al. Emergency Cervical Internal Carotid Artery

- Stenting in Combination with Intracranial Thrombectomy in Acute Stroke. *AJNR Am J Neuroradiol* 2014;35(4):741-6.
5. Taylor RA, Kasner SE. Treatment of Intracranial Arterial Stenosis. *Expert Rev Neurother* 2006;6(11):1685-94.
 6. Hommel M. Cerebrovascular Diseases. In: Ropper AH, Samuels MA, Klein JP, editors. *Adams and Victor's Principles of Neurology*: 10th ed, New York: McGraw-Hill; 2014; 778-884.
 7. Wade Smith, et al. Cerebrovascular Diseases. In: Stephen Hauser, et al. *Harrison's Neurology In Clinical Medicine*. 3rd ed, New York: By McGraw – Hill Education; 2013.
 8. Alexandrov AV, Felberg RA, Demchuk AM, Christou I, Burgin WS, Malkoff M, et al. Deterioration Following Spontaneous Improvement: Sonographic Findings in Patients with Acutely Resolving Symptoms of Cerebral Ischemia. *Stroke* 2000;31(4):915-9.
 9. Razumovsky AY, Gillard JH, Bryan RN, Hanley DF, Oppenheimer SM. TCD, MRA and MRI in Acute Cerebral Ischemia. *Acta Neurologica Scandinavica* 1999;99(1):65-76.
 10. Akopov S, Whitman GT. Hemodynamic Studies in Early Ischemic Stroke: Serial Transcranial Doppler and Magnetic Resonance Angiography Evaluation. *Stroke* 2002;33(5):1274-9.
 11. Demchuk AM, Christou I, Wein TH, Felberg RA, Malkoff M, Grotta JC, et al. Accuracy and Criteria for Localizing Arterial Occlusion with Transcranial Doppler. *J Neuroimaging* 2000;10(1):1-12.
 12. Levi CR. Transcranial Ultrasound - Clinical Applications In Cerebral Ischemia. *Australian Prescriber* 2001;24(6):137-140.
 13. McCartney JP, Thomas-Lukes KM, Gomes CR. *Handbook Of Transcranial Doppler; Principles And Strategies For TCD Interpretation*. New York; Springer-Verlag; 1997.
 14. Alexandrov AV, Mikulik R, Demchuk A. Ultrasound in Acute Stroke: Diagnosis, Reversed Robin Hood Syndrome and Sonothrombolysis. In: Alexandrov AV (ed). *Cerebrovascular Ultrasound in Stroke Prevention and Treatment*. 2ed ed, Hoboken, New Jersey: Wiley-Blackwell; 2011.
 15. Alexandrov A. Diagnostic Criteria For Cerebrovascular Ultrasound. In: Tsivgoulis G, Neumyer M, Alexandrov A, editors. *Cerebrovascular Ultrasound in Stroke Prevention and Treatment*. 2ed ed: Wiley-Blackwell; 2011.
 16. Lyrer PA, Engelter S, Radu EW, Steck AJ. Cerebral Infarcts Related to Isolated Middle Cerebral Artery Stenosis. *Stroke* 1997;28(5):1022-7.
 17. Jackson C, Sudlow C. Are Lacunar Strokes Really Different? A Systematic Review of Differences in Risk Factor Profiles Between Lacunar and Nonlacunar Infarcts. *Stroke* 2005;36(4):891-901.
 18. Chamorro A, Sacco RL, Mohr JP, Foulkes MA, Kase CS, Tatemichi TK, et al. Clinical-Computed Tomographic Correlations of Lacunar Infarction in the Stroke Data Bank. *Stroke* 1991;22(2):175-81.
 19. Alpert JN. Extracranial carotid artery. Current Concepts of Diagnosis and Management. *Tex Heart Inst J* 1991;18(2):93-7.
 20. Rajajee V, Fletcher JJ, Pandey AS, Gemmete JJ, Chaudhary N, Jacobs TL, et al. Low Pulsatility Index on Transcranial Doppler Predicts Symptomatic Large-Vessel Vasospasm after Aneurysmal Subarachnoid Hemorrhage. *Neurosurgery* 2012;70(5):1195-206.
 21. Costopoulos C, Liew TV, Bennett M. Ageing and Atherosclerosis: Mechanisms and Therapeutic Options. *Biochem Pharmacol* 2008;15;75(6):1251-61.
 22. Wang JC, Bennett M. Aging and Atherosclerosis: Mechanisms, Functional Consequences, and Potential Therapeutics for Cellular Senescence. *Circ Res* 2012; 6;111(2):245-59.