



Benign Paroxysmal Positional Vertigo Prevalence in Meniere's Disease: Is Meniere's Disease a Predisposing Factor?

Motasaddi-Zarandi Masoud (MD)^{1,2}, Nemati Shadman (MD)^{3,4*}, Panahi Rasoul (PhD stu)⁵, Akbari Maryam (MD)⁶

ARTICLE INFO

Article type:
Original Article

Article history:
Received: 15 October 2014
Accepted: 12 January 2015
Available online: 20 March 2015
CJNS 2015; 1 (1): 7-11

1. Otolaryngology- Head & Neck Surgery Department, Faculty of Medicine, Tehran University of Medical Sciences, Tehran, Iran
2. Otorhinolaryngology Research Center, Tehran University of Medical Sciences, Tehran, Iran
3. Otorhinolaryngology- Head & Neck Surgery Department, Faculty of Medicine, Guilan University of Medical Sciences, Rasht, Iran
4. Rhinosinus Research Center, Guilan University of Medical Sciences, Rasht, Iran
5. Shahid Beheshty University of Medical Sciences, Tehran, Iran
6. Otorhinolaryngology- Head & Neck Surgery Department, Faculty of Medicine, Guilan University of Medical Sciences, Rasht, Iran

***Corresponding author:**

Otorhinolaryngology- Head & Neck Surgery department, Faculty of Medicine, Guilan University of Medical Sciences, Rasht, Iran
Email: drshadmannemati_ent@yahoo.com

ABSTRACT

Background: Meniere's disease (MD) is a chronic illness defined as an idiopathic syndrome of endolymphatic hydrops. Benign paroxysmal positional vertigo (BPPV) is a balance disorder and can be the sequel of diverse inner ear impairments.

Objectives: The purpose of this study was to investigate the prevalence of BPPV in MD patients.

Materials and Methods: All patients with definite or probable MD participated in this cross-sectional descriptive and analytic study between March 2013 and February 2014. We used the American Academy of Otolaryngology-Head and Neck Surgery (AAO-HNS) criteria plus electrocochleography (ECoChG) test results to define the presence of MD and positional tests to determine the presence of BPPV. The frequency was reported. Independent sample t-test was also used in SPSS19.

Results: A total of 39 patients (43 ears) with definite or probable MD (26 female, 13 male; mean age: 46.4 ± 9.2 years) were enrolled in this study. Six out of 39 cases (15.4%) had BPPV in the posterior semicircular canal. The mean duration of MD was 28.5 months in BPPV group and 13.2 months in the non-BPPV group. Regardless of the age of the patients, there was a significant difference ($p = 0.02$) between the duration of MD in the two groups.

Conclusions: It seems that MD and BPPV are related and a longer duration of MD may result in a greater risk of developing BPPV.

Keywords: Meniere Disease; Benign Paroxysmal Positional Vertigo

Copyright © 2015 Caspian Journal of Neurological Sciences. All rights reserved.

➤ **Please cite this paper as:**

Motasaddi-Zarandi M, Nemati Sh, Panahi R, Akbari M. Benign Paroxysmal Positional Vertigo Incidence in Meniere's Disease: Is Meniere's Disease a Predisposing Factor?. Caspian J Neurol Sci 2015; 1(1):7-11.

Introduction

Meniere's disease (MD) is a chronic illness defined as an idiopathic syndrome of endolymphatic hydrops. The disease is characterised by recurrent spontaneous episodes of vertigo, fluctuating hearing loss, aural fullness or pressure and tinnitus (1). A

large number of factors have been proposed as precursors to the development of endolymphatic hydrops, including excessive endolymph production, decreased endolymph absorption by the endolymphatic sac, ionic imbalance, genetic abnormalities, viral infections, dietary factors, vascular

irregularities and others (2). According to the guidelines from the Committee on Hearing and Equilibrium of the American Academy of Otolaryngology–Head and Neck Surgery (AAO-HNS), three major symptoms must be present in order to make a diagnosis of MD: vertigo, hearing loss and tinnitus (3). If the hydrops is a causative factor and not an epiphenomenon, then electrocochleography (ECoChG) would be an ideal diagnostic test (4). ECoChG measures the cochlear microphonic (CM), the summing potential (SP) and the action potential (AP). The CM is produced by the outer hair cells within the cochlea and is its resting receptor potential. The SP is the direct current endocochlear potential produced by a sound stimulus. The AP is the sum of synchronous auditory neural potentials. In endolymphatic hydrops, the hydropic conditions displace the basilar membrane, which also displaces the stereocilia of the hair cells. Therefore, the resting potential (CM) is altered. With a sound stimulus, an enhanced negative SP occurs. Thus, an elevated SP/AP ratio is thought to reflect endolymphatic hydrops (4). An elevated SP/AP ratio measured by ECoChG has long been considered to be the electrophysiological correlate of the clinical conditions related to endolymphatic hydrops, such as MD (5). A recent study using a mouse model of Post-natal endolymphatic hydrops demonstrated that an elevated SP/AP ratio is diagnostic of endolymphatic hydrops (6).

Benign paroxysmal positional vertigo (BPPV) is likely the most common diagnosis identified in vertigo and balance clinics and can be the sequel of diverse inner ear impairments (3, 7-9). Although the pathogenesis of BPPV has been controversial,

it has been widely accepted that BPPV is caused by basophilic material adherent to the cupula of the semicircular canal (cupulolithiasis) or free-floating material derived from degenerative otoconia in the lumen of the semicircular canal (canalithiasis) (3, 7, 10, 11).

Recurrent episodic vertigo is one of the fundamental symptoms of MD, whereas positional vertigo is often seen in patients with MD during and between attacks of episodic vertigo (8, 11). Also, there are reports that floating deposits in the semicircular canals and the symptom of positional vertigo in patients with MD are correlated (8, 11-14). The purpose of this study was to investigate the prevalence of BPPV in our patients with MD and to denote the possible role of MD in the development of positional vertigo.

Materials and Methods

This was a cross-sectional descriptive and analytic study. All patients with suspected MD were referred to our ENT clinic in Guilan, Iran, between March 2013 and February 2014. They underwent complete case history and standard audiometry. Patients with a history of cochleovestibular disease (such as vestibular neuritis or chronic otitis media), head trauma or surgery, or prolonged bed rest were excluded from the study. MD is defined as definite, probable, or possible (3). We used the AAO-HNS criteria plus ECoChG test results to define the presence of probable or definite MD. These criteria include definitive spontaneous episodes of true vertigo lasting for 15-20 minutes, audiometrically documented hearing loss on at least one occasion, tinnitus or sense of aural fullness in the presumed affected ear and

exclusion of other causes (one for probable MD or two or more for definite MD) (3). Extra-tympanic ECoChG was done using the Neurosoft EP System (© Neurosoft, Ivanovo, Russia). For ECoChG testing we used alternating click stimuli of 100 milliseconds at a rate of 7.1/second at 90 dB of hearing level, presented monaurally. The reference electrode was placed on the forehead, whereas the ground was placed on the non-test ear lobe. The SP and AP amplitudes were obtained and the average of two trials was used. An SP/AP ratio of greater than 0.40 was considered abnormal.

The diagnosis of BPPV was made by the patients' history and physical examination findings. Positional and positioning tests (Dix–Hallpike manoeuvre) were used to find the presence of episodes of true vertigo lasting for less than 1 minute that occurred with changing head position. These procedures were sometimes repeated in up to four sessions to confirm true episodes of vertigo with the typically associated eye movements, delay and fatigability.

The relative frequency of BPPV was reported among MD patients. Finally, we used the independent sample t-test to investigate the relationship between the duration of MD and BPPV. All data analysis was done in SPSS software version 19.

Results

Thirty-nine patients with definite or probable MD participated in the study, consisting of 26 women (67%) and 13 men (33%). The mean age of patients was 46.4 ± 9.2 years. Four patients had bilateral MD; therefore, we had 43 ears to test. Average audiogram data of patients is presented in diagram 1. Twenty eight of the 43 ears (65.1%) had abnormal

ECoChG test results.

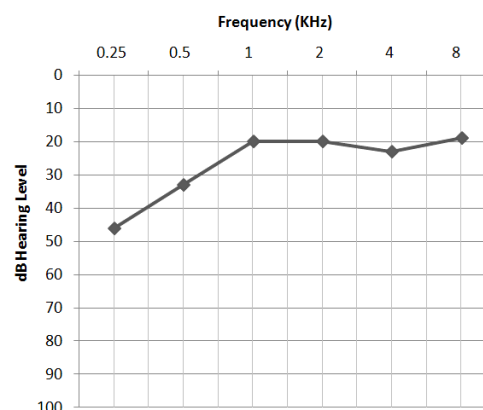


Diagram 1: The average audiogram in 43 ears with definite or probable Meniere's disease

Six out of 39 cases (15.4%) had BPPV in the posterior semicircular canal (4 female, 2 male; mean age of 48.2 ± 8.8 years). No one had BPPV in the lateral or superior semicircular canals. All of these patients had Meniere's symptoms before the onset of BPPV. The mean duration of MD was 28.5 months in patients with BPPV and 13.2 months in the non-BPPV group. Comparison between the duration of MD in the two groups using the independent samples t-test showed a significant difference ($p = 0.02$). These results were independent of aging.

Discussion

Electrocochleography (ECoChG) is the recording of an electrophysiological event which takes place in the cochlea after an acoustical stimulus. There are many studies that have examined the relationship between ECoChG test results and MD. Some of these studies have reported that because of its lack of sensitivity, ECoChG should not play a decisive role in determining the presence or absence of MD (3, 15). For instance, Kim et al. in a retrospective case review study reported that 59.8% of patients undergoing

extra-tympanic ECoChG for MD had abnormally elevated SP/AP ratios (4). On the other hand, many studies concluded that it is a useful method for diagnosing and evaluating patients with MD. Martín-Sanz et al. considered an increased SP/AP ratio as characteristic of endolymphatic hydrops. They reported that 85% of 100 patients had an SP/AP ratio above 0.5 (5). In the present study, about 65% of patients had elevated SP/AP ratios. The results of this study can be used for commenting about the relationship between ECoChG test results and MD. Overall, the prevalence of BPPV has been reported to range from 10.7 to 64 per 100,000 people with a lifetime prevalence of 2.4 percent (3, 16). Some types of BPPV that occur after an inner ear disease are called secondary BPPV (s-BPPV). Although the aetiology of idiopathic BPPV (i-BPPV) remains obscure, morphological changes in vestibular otoconia are thought to be a major cause. In contrast, the varied etiologies of s-BPPV have been known and include head trauma, viral neurolabyrinthitis, MD, otologic surgery and ototoxic drugs (17). The association of BPPV and MD has occasionally been reported (11-14, 17). There are also reports of incidence rates of MD among patients with BPPV as low as 0.5% and as high as 31% (10, 14). Balatsouras et al. found a prevalence of 8.4% of this clinical entity in patients with BPPV. They examined 345 patients diagnosed with BPPV. Among them, 29 patients had been previously diagnosed with MD (18). In the present study we found that 15.4% of our patients had BPPV secondary to MD. Also, results of this investigation showed that patients who had BPPV with MD had a longer history of MD. Comparisons of duration of MD among patients with and without BPPV showed a

considerable difference. Morita et al. also found a significant correlation between the incidence of cupular deposits and duration of disease in bilateral MD (11). Gross et al. provided a description of the coexistence of BPPV and MD (12). They reported that 5.6% of their patients had both MD and BPPV. Meniere's symptoms preceded the onset of BPPV in all of them, and except for one patient who experienced BPPV bilaterally; BPPV was limited to the same ear as well as the MD. All patients in our study also had Meniere's symptoms before onset of BPPV.

It should be considered that hydrops of the cochlea and/or vestibular system is not necessarily associated with a history of episodic vertigo (2). This could be another reason for the hypothesis of s-BPPV, although the lack of vestibular symptoms in patients with hydrops can be explained on the basis, that symptoms were present, but not documented in the medical history. However, hydropically induced damage to the maculae of the utricle and saccule may be a possible mechanism that leads to eardust falling off into the semicircular canals (12, 13). Partial obstruction of the membranous labyrinth may be a possible explanation of the coexistence of MD and BPPV (12). Besides, free-floating otoliths could induce hydrops by mechanically obstructing the longitudinal flow and absorption of endolymph (8). Therefore, it seems that MD may harbour a greater risk of developing BPPV.

Conclusion

Based on our findings, MD and BPPV are related. Also a longer duration of MD may result in a greater risk of development of BPPV and the incidence of BPPV is affected more by duration of disease and condition of the labyrinth than by aging.

Conflict of Interest

No conflict of interest.

References

1. Moon IJ, Park GY, Choi J, Cho YS, Hong SH, Chung WH. Predictive Value of Electrocochleography for Determining Hearing Outcomes in Ménière's Disease. *Otol Neurotol* 2012;33(2):204-10.
2. Merchant SN, Adams JC, Nadol Jr JB. Pathophysiology of Meniere's Syndrome: Are Symptoms Caused by Endolymphatic Hydrops?. *Otol Neurotol* 2005;26(1):74-81.
3. Crane BT, Schessel DA, Nedzelski J, Minor LB. "Peripheral vestibular disorders". Flint PW, Haughey BH, Lund VJ, et al. (eds). *Cummings Otolaryngology: Head & Neck Surgery*. 5th ed. Philadelphia: Mosby-Elsevier; 2010.
4. Kim HH, Kumar A, Battista RA, Wiet RJ. Electrocochleography in Patients with Meniere's Disease. *Am J Otolaryngol* 2005;26(2):128-31.
5. Martín-Sanz E, Sánchez JE, Juliao MG, Zschaecck Luzardo C, Mato Patino T, Rodríguez Riesco L, et al. Extratympanic Electrocochleography in Meniere's Disease. *Acta Otorrinolaringol Esp* 2012;63(6):421-8.
6. Melki SJ, Li Y, Semaan MT, Zheng QY, Megerian CA, Alagramam KN. A Mouse Model Validates the Utility of Electrocochleography in Verifying Endolymphatic Hydrops. *J Assoc Res Otolaryngol* 2014;15(3):413-21.
7. Zappia JJ. Benign Paroxysmal Positional Vertigo. *Curr Opin Otolaryngol Head Neck Surg* 2013;21(5):480-6.
8. Perez N, Martin E, Zubieta JL, Romero MD, Garcia-Tapia R. Benign Paroxysmal Positional Vertigo in Patients with Meniere's Disease Treated with Intratympanic Gentamycin. *Laryngoscope* 2002; 112(6): 1104-9.
9. Saberi A, Nemati Sh, Pourafshar P. Clinical, Demographic and Paraclinical Finding in Peripheral and Central Vertigo. *J Guilan Uni Med Sci*. 2014; 23 (91): 1-7. [Text In Persian]
10. Hughes CA, Proctor L. Benign Paroxysmal Positional Vertigo. *Laryngoscope* 1997; 107 (5): 607-13
11. Morita N, Cureoglu S, Nomiya S, Nomiya R, Joglekar SS, Harada T, et al. Potential Cause of Positional Vertigo in Meniere's Disease. *Otol Neurotol* 2009;30(7):956-60.
12. Gross EM, Ress BD, Viirre ES, Nelson JR, Harris JP. Intractable Benign Paroxysmal Positional Vertigo in Patients with Meniere's Disease. *Laryngoscope* 2000;110(4):655-9.
13. Li P, Zeng XL, Li YQ, Zhang GH, Ye J. The Clinical Characteristics of the Benign Paroxysmal Positional Vertigo Associated with Meniere's Disease. *Zhonghua Yi Xue Za Zhi* 2010;90(27):1921-3.
14. Karlberg M, Hall K, Quickert N, Hinson J, Halmagyi GM. What Inner Ear Diseases Cause Benign Paroxysmal Positional Vertigo?. *Acta Otolaryngol* 2000;120(3):380-5.
15. Paparella MM, Djalilian HR. Etiology, Pathophysiology of Symptoms, and Pathogenesis of Meniere's Disease. *Otolaryngol Clin North Am* 2002;35(3):529-45.
16. Bhattacharyya N, Baugh RF, Orvidas L, Barrs D, Bronston LJ, Cass S, et al. Clinical practice guideline: Benign paroxysmal positional vertigo. *Otolaryngol Head Neck Surg* 2008;139 (5 Suppl 4): S47-81.
17. Lee NH, Ban JH, Lee KC, Kim SM. Benign Paroxysmal Positional Vertigo Secondary to Inner Ear Disease. *Otolaryngol Head Neck Surg* 2010;143(3):413-7.
18. Balatsouras DG, Ganelis P, Aspris A, Economou NC, Moukos A, Koukoutsis G. Benign Paroxysmal Positional Vertigo Associated with Meniere's Disease: Epidemiological, Pathophysiologic, Clinical, and Therapeutic Aspects. *Ann Otol Rhinol Laryngol* 2012;121(10):682-8.