

Traumatic Pneumorrhachis in a Young Male Motor Vehicle Accident Victim

Behzadnia Hamid (MD)¹, Alijani Babak (MD)^{1*}, Ramzannezhad Armin (MD)¹, Dehghani Siavash (MD)¹

ARTICLE INFO

Article type:
Case Report

Article history:

Received: 15 October 2016
Accepted: 9 December 2016
Available online: 30 December 2016
CJNS 2016; 2 (7): 49-54

1. Poursina Hospital, Guilan University of
Medical Sciences, Rasht, Iran

***Corresponding author:**

Poursina Hospital, Guilan University of
Medical Sciences, Rasht, Iran

Email: babakalij@gmail.com

ABSTRACT

Pneumorrhachis (PR), which involves the entrapment of air or gas within the spinal canal, is a rare clinical entity. The pathogenesis and etiology of this uncommon entity vary and may present a diagnostic challenge. Air in the spinal canal can be divided into primary and secondary PR, extra- or intradural PR and etiologically classified as iatrogenic, traumatic and non-traumatic. PR is typically asymptomatic but can be symptomatic—by itself or by its underlying pathology. The latter, although often severe, might be concealed and must be carefully examined to facilitate adequate patient treatment. Here we report a rare case of traumatic PR in a 28-year old man following a motor vehicle accident in northern Iran, who sustained paraplegia and sphincter dysfunction without any laceration and wound in the spinal area.

Keywords: Pneumorrhachis; Trauma

Copyright © [2016] Caspian Journal of Neurological Sciences. All rights reserved.

➤ **Please cite this paper as:**

Behzadnia H, Alijani B, Ramzannezhad A, Dehghani S. Traumatic Pneumorrhachis in a Young Male Motor Vehicle Accident Victim. Caspian J Neurol Sci 2016; 2(7):49-54.

Introduction

Pneumorrhachis (PR) is characterized by air entrapped within the spinal canal, either in the epidural or intradural space [1]. It is a rare condition, generally associated with trauma and surgical procedures; there are various etiologies and possible pathways of air entry into the spinal canal [2]. The causes can be classified as iatrogenic, non-traumatic and traumatic, the last of which is most rare. Its precise mechanisms remain unknown. PR is typically

asymptomatic and clinically non-specific. It does not tend to migrate, but it gets spontaneously reabsorbed into the bloodstream over a period of several days. Patients with PR are thus typically treated conservatively [3].

PR secondary to trauma is rare, though it has been observed in patients with bone fractures and spinal injuries. Pain and neurological injury is uncommon in these injuries, and they are often diagnosed

incidentally by radiographic imaging, such as computed tomography (CT) scanning [2-6]. We report a rare case of traumatic PR accompanied by paraplegia by reviewing the other literatures.

Case Presentation

A 28-year old man was admitted to the hospital following a motor vehicle accident (MVA). He presented with a Glasgow coma scale of 12 (E4M5V3) and mid-sized pupil. On admission, he was unstable, with 80 mmHg systolic blood pressure and tachycardia. During physical examination, according to the manual muscle test, the

muscular strength of his upper extremities was normal (5/5), with paraplegia as a result of T11 fracture and cord injury, and tenderness of the thoracic spinal region. The patient complained of sphincter dysfunction in form of urinary incontinence. The skin surface was intact and there were no signs of penetrating wound.

The chest radiograph did not indicate rib fracture. Whole spine axis X-ray and CT were performed and a T11 seat belt-type fracture with Clay Shoveler's fracture of T1-T2 was revealed, with air entrapment from C3 to C7 of the spinal canal. Cervicothoracic MRI confirmed previous findings. (Figs 1-3)

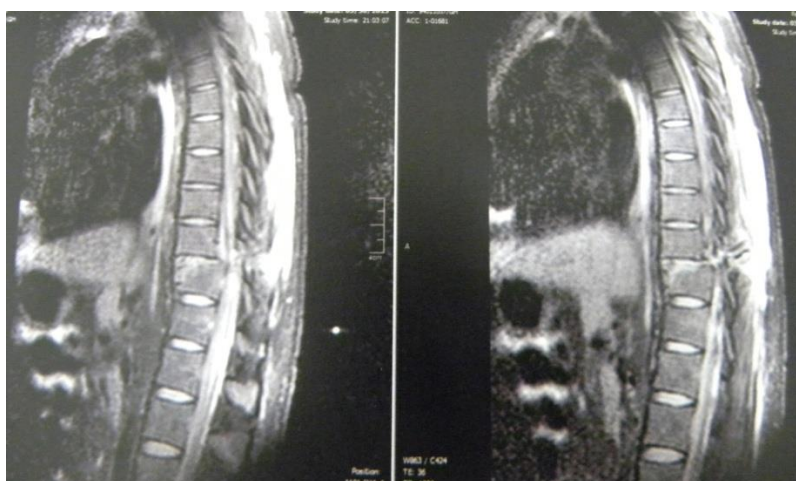

Figure 1. Sagittal magnetic resonance imaging (MRI) demonstrates fracture of the T11.

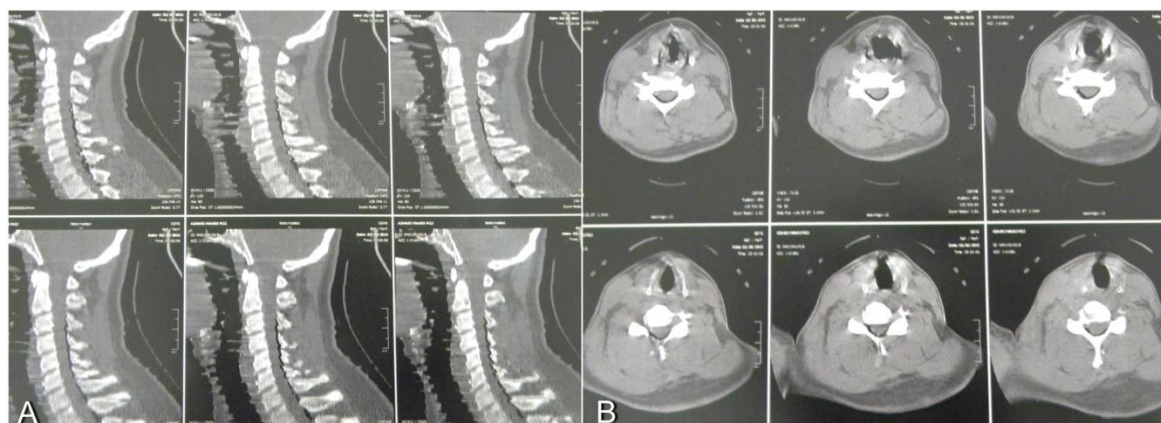


Figure 2. Sagittal multilane reformatted spinal CT images demonstrating traumatic cervical PR (A). Axial CT scan of the cervical spine shows extradural air collection in the dorsal spinal canal.

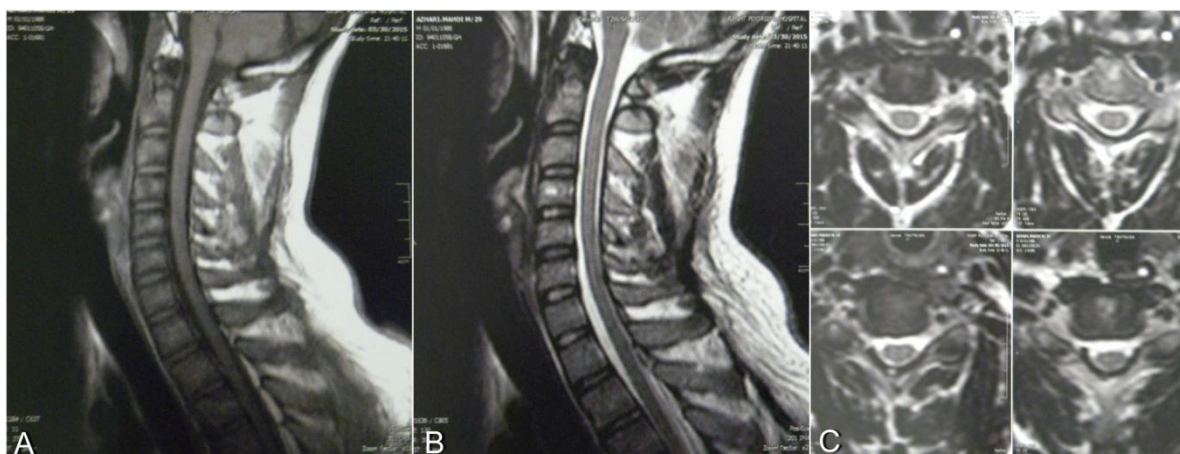


Figure 3. Sagittal T1-weighted (A), sagittal T2-weighted (B), and axial T2-weighted (C) MR images show posterior epidural air in the cervical spinal canal.

The patient was a candidate for posterior dorsal pedicular screw fixation. However, according to the detection of intraspinal air, surgery was postponed. After one week of conservative treatment, the patient regained consciousness. Physicians repeated the neurological examinations. The patient presented with paraplegia and sphincter dysfunction, without any changes. On follow-up CT of the cervico-thoracic spine, there was no trace of intraspinal air. The operation was performed successfully, eight days post-trauma, by posterior fixation method. No PR-related complications were observed.

Discussion

The term PR was first used by Gordon and Hardman in 1977 [7,8]. PR is a rare condition, characterized by the presence of air in the intraspinal canal, which is usually diagnosed incidentally while examining coincidental injuries and disease. It almost always presents in combination with the presence of air in other cavities and coincident underlying injuries and diseases. In addition, in this case, the mechanism of injury was accidental, without lacerations and

wounds. Improved imaging technology has increased PR diagnoses [2]. The air could be detected using images, such as plain radiograph, magnetic resonance imaging (MRI), and computerized tomography (CT) scanning, the last of which is especially helpful [2,9].

Different etiologies and possible pathways of air entry into the spinal canal are presumed, and can be classified descriptively as primary, secondary, traumatic, non-traumatic, intradural, and extradural (epidural or subarachnoid) [2,3,8-13]. Iatrogenic PR can result from various surgical interventions, anesthetics, and certain diagnostic techniques [4,6,14]. Non-traumatic etiologies include vertebral degeneration, malignancy and its associated therapy, infectious diseases by gas-forming organisms, etc. [14,15]. PR secondary to traumatic causes is rare and includes head, cervical, thoracic, abdominal and pelvic injuries or combinations of different injuries, including spinal trauma [16-18]. Traumatic and subarachnoid PR alone is frequently associated with major trauma and believed to be a marker of severe injury [6,8,10]. In this case, the etiology

appears secondary, with unknown cause.

PR is usually asymptomatic and clinically non-specific. It is a primarily radiographic diagnosis but not a clinical one. The air in the spinal cord does not tend to migrate, and usually is spontaneously reabsorbed into the bloodstream over a period of several days [2,19,20]. Interestingly, in our case, the air trap was observed in the cervical spine but the fracture detected in T11.

There are a few reported cases of patients reporting discomfort and sensory disturbances; PR patients are typically managed conservatively [6,12,21,22]. Failure to diagnose and treat PR early can delay recovery and worsen prognosis [12,23]. In this case as well as in others, no sensory disturbances were observed. Intraspinial air must be clearly differentiated from free intraspinal gas collections owing to degenerative, malignant, inflammatory, and infectious diseases by gas-forming organisms [9].

Spontaneous resolution occurs in most cases of epidural space PR, which permits conservative management [19,20,24]. There is no standard guideline for the treatment of PR. PR is apparently associated with increased morbidity and mortality [2,12]. Entrapped intraspinal air, in combination with a one-way air valve mechanism, might cause tension PR and pneumocephalus with nervous tissue compression, requiring intervention [2]. In our case, after few days, we checked again with CT and no any air trap was observed in the spinal cord.

If cerebrospinal fluid (CSF) leakage persists, this could be managed by serial lumbar puncture or lumbar drainage [2,25,26]. Fistulae pathways with other cavities might require surgical innervations

[27-29]. Prophylactic management with antibiotics is typically not recommended in cases of extradural PR and in patients with intradural PR without signs and symptoms of meningitis [9]. Other treatment modalities include transient high concentration oxygen therapy to achieve nitrogen washout, which is recommended in some articles [2,12,24,30]. The management of patients with PR must be individualized according to associated pathologies, requiring inter- and multidisciplinary control [2]. In the present case, no CSF leaks were noted; we administered only oxygen therapy.

The use of inhalational nitrous oxide, in cases in which general anesthesia is required, is avoided because it induces the expansion of intracavitary gas volume and results in increased intracranial pressure, owing to its diffusion into the air-filled space. Also, pressurization of the oronasopharynx should be avoided, and alternative anesthetic techniques, such as intermittent positive pressure ventilation (IPPV) with transient high concentration oxygen, are the methods of choice, preventing an increase in the volume of any intraspinal and intracranial air and simultaneously promoting faster reabsorption of air [9,31].

Conclusion

PR is a rare clinical entity and caused by a multitude of sources. Early detection, proper neurological examination, and rehabilitation evaluation are crucial for the treatment of PR secondary to trauma accompanied by neurological symptoms. It is typically self-limiting, without further therapeutic consequences. Management is directed to associate pathologies, to enable adequate therapy.

Conflict of Interest

The authors have no conflict of interest.

References

- Copetti R, Mattei G. Traumatic Epidural Pneumorrhachis. *BMJ Case Rep* 2010; bcr 0120102692.
- Oertel MF, Korinth MC, Reinges MH, Krings T, Terbeck S, Gilsbach JM. Pathogenesis, Diagnosis and Management of Pneumorrhachis. *Eur Spine J* 2006;15(5):636-43.
- Goh BK, Yeo AW. Traumatic Pneumorrhachis. *J Trauma* 2005;58(4):875-9.
- Prabhakar H, Bithal PK, Ghosh I, Dash HH. Pneumorrhachis Presenting as Quadriplegia Following Surgery in the Prone Position. *Br J Anaesth* 2006;97(6):901-3.
- Uemura K, Behr R, Roosen K. Symptomatic Intraspinial Air Entrapment. *Br J Neurosurg* 2000;14(2):154-6.
- Krishnam, Mallick A. Air in the Epidural Space Leading to a Neurological Deficit. *Anaesthesia* 2003;58(3):292-3.
- Gordon IJ, Hardman DR. The Traumatic Pneumomyelogram. A previously undescribed entity. *Neuroradiology* 1977;13(2):107-8.
- Arora S, Aggarwal P, Cheema GS, Singla J. Pneumorrhachis of the Cervical Spine with Associated Pneumocephalus and Subcutaneous Emphysema. *Indian J Orthop* 2011;45(4):372-5.
- Dwarakanath S, Banerji A, Chandramouli BA. Posttraumatic Intradural Pneumorrhachis: A Rare Entity. *The Indian Journal of Neurotrauma* 2009;6(2):151-2.
- Gelalis ID, Karageorgos A, Arnaoutoglou C, Gartzonikas D, Politis A, Georgakopoulos N, et al. Traumatic Pneumorrhachis: Etiology, Pathomechanism, Diagnosis, and Treatment. *Spine J* 2011;11(2):153-7.
- Kim KY, Kang JH, Lee MH, Han Y, Choi DW. Atypical Traumatic Pneumorrhachis Accompanied by Paraparesis. *Ann Rehabil Med* 2014;38(3):410-4.
- Yousaf I, Flynn P, McConnell R. Symptomatic Intraspinial Pneumocoele Resulting from Closed Head Injury. *Br J Neurosurg* 2003;17(3):248-9.
- Park JS, Kim H, Lee SW, Min JH, Kim SW, Lee KW. Symptomatic Pneumorrhachis after Chest Tube Insertion for Spontaneous Pneumothorax. *Am J Emerg Med* 2010;28(7):846 e1-2.
- Gautschi OP, Hermann C, Cadosch D. Spinal Epidural Air after Severe Pelvic and Abdominal Trauma. *The Am J Emerg Med* 2008;26(6):740 e3-5.
- Yanagawa Y, Takasu A, Sugiura T, Okada Y. A Case of Cervical Pneumorrhachis Induced by the Combination of Pneumomediastinum and Root Avulsion Injuries. *Eu Spine J* 2007;16(4):573-4.
- Kakitsubata Y, Theodorou SJ, Theodorou DJ, Yuko M, Ito Y, Yuki Y, et al. Symptomatic Epidural Gas Cyst Associated with Discal Vacuum Phenomenon. *Spine* 2009;34(21):E784-9.
- Wang YX, Griffith JF, Zeng XJ, Deng M, Kwok AW, Leung JC, et al. Prevalence and Sex Difference of Lumbar Disc Space Narrowing in Elderly Chinese Men and Women: Osteoporotic Fractures in Men (Hong Kong) and Osteoporotic Fractures in Women (Hong Kong) Studies. *Arthritis Rheum* 2013;65(4):1004-10.
- Macia I, Moya J, Ramos R, Morera R, Escobar I, Saumench J, et al. Spontaneous Pneumomediastinum: 41 Cases. *Eur J Cardiothorac Surg* 2007;31(6):1110-4.
- Willing SJ. Epidural Pneumatosis: a Benign Entity in Trauma Patients. *AJNR Am J Neuroradiol* 1991;12(2):345.
- Tsuji H, Takazakura E, Terada Y, Makino H, Yasuda A, Oiko Y. CT Demonstration of Spinal Epidural Emphysema Complicating Bronchial Asthma and Violent Coughing. *J Comput Assist Tomogr* 1989;13(1):38-9.
- Carolan PL, Wright SL, Jha V. Spontaneous Pneumorrhachis. *Pediatr Emerg Care* 2013;29(4):508-9.
- Huang HR, Wong KS, Lien R, Chiu CY. Spontaneous Pneumomediastinum Due to Gastroesophageal Reflux Disease in an Adolescent Boy. *Respirology* 2008;13(5):744-5.

23. Panacek EA, Singer AJ, Sherman BW, Prescott A, Rutherford WF. Spontaneous Pneumomediastinum: Clinical and Natural History. *Ann Emerg Med* 1992;21(10):1222-7.
24. Hazouard E, Koninck JC, Attucci S, Fauchier-Rolland F, Brunereau L, Diot P. Pneumorrhachis and Pneumomediastinum Caused by Repeated Muller's Maneuvers: Complications of Marijuana Smoking. *Ann Emerg Med* 2001;38(6):694-7.
25. Mangiardi JR, Brisson P, Weitzner I, Jr., Bednar M. Traumatic Intraspinale Pneumocele. *SurgNeurol* 1987;27(6):587-8.
26. Oertel MF. Pneumorrhachis of the Entire Spinal Canal. *J Neurol Neurosurg* 2005;76(7):1036.
27. Hwang WC, Kim HC. CT Demonstration of Spinal Epidural Air after Chest Trauma. *Eur Radiol* 2000;10(2):396-7.
28. Weber P, Vastmans J, Gartner C, van Boemmel T, Hofmann GO. Bronchial Rupture Combined with Luxation Fracture of the Thoracic Spine Following Direct Trauma. *Der Unfallchirurg* 2004;107(11):1093-8.
29. Scialdone CJ, Wagle W. Intraspinale Air: an Unusual Manifestation of Blunt Chest Trauma. *Clin Imaging* 1990;14(1):59-60.
30. Day CJ, Nolan JP, Tarver D. Traumatic Pneumomyelogram. Implications for the Anaesthetist. *Anaesthesia* 1994;49(12):1061-3.
31. El-Halabi D, Alkandari T, Yaktien MM. Traumatic Air in Spinal Canal (Pneumorrhachis). *Anaesthesiol Intensive Ther* 2012;44(1):25-7.