



## Asterixis as a Focal Neurologic Sign: Report of Three Cases and Literature Review

Sayadnasiri Mohammad (MD)<sup>1\*</sup>, Altafi Davar (MD)<sup>2</sup>

### ARTICLE INFO

**Article type:**  
 Case Report

### Article history:

Received: 16 September 2015  
 Accepted: 7 January 2016  
 Available online: 30 June 2016  
 CJNS 2016; 2 (5): 54-58

1. Assistant Professor of Neurology, Department of Clinical Sciences, University of Social Welfare and Rehabilitation Sciences, Tehran, Iran
2. Neurologist, Department of Neurology, Alavi University Hospital, Ardabil, Iran

### \*Corresponding author:

Assistant Professor of Neurology,  
 Department of Clinical Sciences,  
 University of Social Welfare and  
 Rehabilitation Sciences, Tehran,  
 Iran  
 Email: nasiri115@yahoo.com

### ABSTRACT

Asterixis, firstly described in metabolic encephalopathies, may occur unilaterally in patients with various focal brain diseases. Although hardly localizing, most reported cases have showed a contralateral thalamic pathology; but Lesions in the medial frontal lobe, parietal lobe, brain stem, basal ganglia, insular lesions, may also cause unilateral asterixis. In this article, three cases of acute cerebral vascular event with unilateral or asymmetrical asterixis were described: first patient with left sided hemiparesis and asterixis that ultimately diagnosed as right thalamic hemorrhage; second patient with right sided hemiparesis and asterixis after acute left thalamic infarction and a patient with transient right sided weakness and bilateral asymmetrical asterixis secondary to a transient ischemic attack in left internal carotid territory. We then provided a literature review of published similar cases to emphasize on asterixis as a focal neurological sign.

**Keywords:** Asterixis; Thalamus

**Copyright © [2016] Caspian Journal of Neurological Sciences. All rights reserved.**

### ➤ Please cite this paper as:

Sayadnasiri M, Altafi D. Asterixis as a Focal Neurologic Sign: Report of Three Cases and Literature Review. Caspian J Neurol Sci 2016; 2(5): 54-58.

### Introduction

**A**sterixis, which is traditionally considered a sign of metabolic cerebral dysfunction, is a form of involuntary movement characterized by intermittent loss of muscle tone during posture maintenance (1). Clinically, it produces the so-called bilateral flapping tremor of asterixis which appears as arrhythmic flexion-extension of the wrist and fingers, several seconds after holding of the upper limbs in an outstretched position but

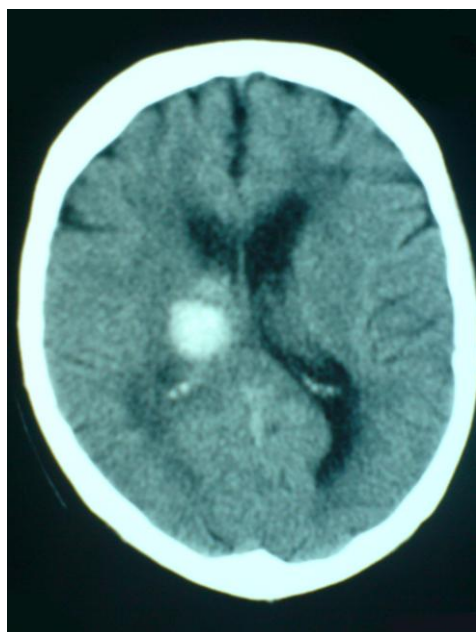
may affect various parts of the body independently. By electrophysiological study, these myoclonic lapses of posture became more apprehensible where involuntary 50- to 200 msec silent periods appeared in both flexors and extensors during downward (flexor) phase of hand asterixis (2,3). In nearly all cases, asterixis is bilateral and associated with toxic-metabolic encephalopathies but it may be infrequently manifested unilaterally so, the possibility of

focal cerebral origin for this sign arose. Reported case series of patients with focal brain lesions and asterixis opened new horizon on the pathophysiologic concept of this sign.

In this paper, we firstly describe three cases of unilateral asterixis and continue with a brief literature review to characterize asterixis as a focal neurologic sign.

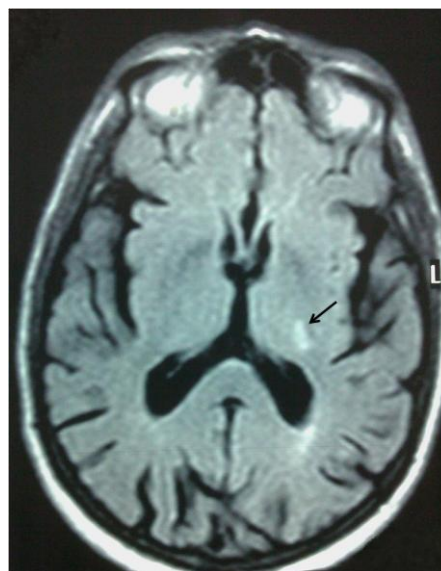
### Case Presentation

Patient 1, a 62 years old man, was referred with headache and gait abnormality to emergency ward. At first examination, patient showed mild left sided weakness and a tendency to fall leftward when walking. In outstretched upper limb position (performed for muscle force evaluation), he manifested a left-sided flapping tremor. Laboratory tests ruled out any underlying metabolic abnormality. Brain CT scan was performed that revealed a right thalamic hematoma (Figure 1).



**Figure 1.** Brain CT scan without contrast showed a right thalamic hematoma in patient 1.

Patient 2, a 62 years old man, presented with sudden mild right sided hemiparesis and sensory loss. At examination, right sided asterixis was evident that recovered after 2 weeks. Brain MRI showed a small thalamic infarct (Figure 2).



**Figure 2.** Brain MRI (FLAIR) showed a small hypersignal lesion of left thalamus due to infarction in patient 2 (arrow).

Patient 3, a 59 years old diabetic man, presented with acute confusional state, right sided hemiparesis and bilateral asterixis more prominent at right side. All findings recovered after 12 hours. Brain MRI (including DWI) revealed no abnormality but Doppler ultrasound of carotid arteries revealed more than 70% stenosis of proximal left internal carotid artery. Laboratory tests were normal.

### Discussion

For the identification of studies included or considered unilateral asterixis, detailed search strategies were developed by searching MEDLINE/PubMed (till 2012). Totally, 26 articles, as we found, described this sign as case reports or case series (4-29). Adams and

Foley first described asterixis in patients with advanced hepatic encephalopathy in 1949 (1) but first report of unilateral asterixis was appeared when Young et al reported unilateral asterixis produced by a discrete CNS lesion (4).

Totally, 125 patients have been reported with unilateral asterixis, as we found. Because of not available some papers' full text, 100 patients with defined cause were analysed and results are as follows:

Of all patients with mentioned definite causes (100 patients), 71 patients (71%) had thalamic lesions; the seconds most common site was cortical area (11%) especially frontal lobe (9%). Other involved areas, in order to frequency, are internal capsule (6%), brain stem (5%), basal ganglia (4%) and cerebellum (3%).

The most frequent cause for unilateral asterixis has been reported to be stroke, either ischemic or hemorrhagic (87%). Other reported causes were rare and included tumors (12,15,24), encephalitis (23), post-surgical (19), subdural hematoma (11). Fourteen patients (11%) presented with bilateral asterixis despite a focal lesion.

Only a few patients with non-stroke etiology manifested this focal sign; this indicates that on contrary to bilateral asterixis resulting from slowly evolving metabolic disturbances, lateralized asterixis often results from an acute disruption of neuronal circuits and chronic focal lesions rarely produce this sign. This susceptibility to acute injury and transient nature of this symptom may be explained by wide ranges of neural pathways affecting posture maintenance, as described below, that leads to rapid brain adjustment and recovery but the main cause is not yet described.

Authors have proposed several different pathophysiologic mechanisms for asterixis; in fact, it is postulated that pathologic structures in reported cases may be a part of the posture maintaining system. Frequent involvement of thalamus or adjacent structures suggested disruption of thalamo-cortical loops as the main pathology (10,12,15,19,20,25,28). Sensory (parietal) cortex involvement in some case reports are also in favour to this afferent motor dysfunction (12). Nighoghossian et al (21) reported patients with primary motor cortex lesion and recommended asterixis may be a disorder of efferent (command signal generator) pathways.

By finding out other involved structures, the pathophysiologic ranges were extended to cerebello-brain stem- thalamus-frontal system dysfunction (26). However, the exact mechanism underlying asterixis remains elusive. Generally, it can be concluded that postural control of limbs is under influence of many brainstem and spinal pathways that are, in turn, are controlled by supratentorial structures (1) and thalamus (especially ventrolateral nucleus) plays a major role in connecting these diverse areas, so it's pathology leads to disruption of these pathways so greatly that clinical asterixis emerges. On the other hand, some cases of bilateral asterixis in the presence of a focal lesion emphasize that this posture controlling system is not necessarily unilateral and this bilateral representation is another explanation for transient nature of this symptom.

Our three reported cases are, also, in agreement with previous reports and underlined thalamic vascular accident as major culprit in development of unilateral asterixis. An interesting part is TIA-like nature of bilateral asterixis in third patient

that rarely reported as yet. This means asterixis, in setting of a focal brain lesion, follows the main features of other focal neurological signs in spite of bilateral presentation.

## Conclusion

Asterixis, bi- or unilateral, may be considered as a focal neurological sign in specific situations. This is a short-lasting sign in patients with focal brain lesions and occasionally may present in setting of a TIA. Although not definitely localizing, a unilateral asterixis is indicative, in most instances, of a contralateral hemispheric lesion especially at thalamic area and often a vascular accident is the underlying cause. So, examining patients for presence of unilateral asterixis, a neglected part of neurologic examination, should be emphasized because it may be helpful in guiding true diagnosis.

## Conflict of Interest

Authors have no conflict of interest.

## References

- Gokula RM, Khasnis A. Asterixis. *J Postgrad Med* 2003; 49:272-5.
- Leavitt S, Tyler HR. Studies in Asterixis. *Arch Neurol* 1964; 10:360-8.
- Young RR, Shahani BT. Asterixis: One Type of Negative Myoclonus. *Adv Neurol* 1986; 43:137-56.
- Young RR, Shahani BT, Kjellberg RJ. Unilateral Asterixis Produced by a Discrete CNS Lesion. *Trans Am Neurol Assoc* 1976; 101:306-7.
- Tarsy D, Lieberman B, Chirico-Post J, D. Benson F. Unilateral Asterixis Associated With a Mesencephalic Syndrome. *Arch Neurol* 1977; 34(7):446-7.
- Ericson G, Warren SE, Gribik M, Channick M, Steinberg SM. Unilateral Asterixis in a Dialysis Patient. *JAMA* 1978; 240(7):671.
- Degos J, Verroust J, Bouchareine A, Serdaru M, Barbizet J. Asterixis in Focal Brain Lesions. *Arch Neurol* 1979; 36(11):705-7.
- Massey EW, Goodman JC. Unilateral Asterixis. *JAMA* 1979; 241(2):133-4.
- Massey EW, Goodman JC, Stewart C, Brannon WL. Unilateral Asterixis: Motor Integrative Dysfunction in Focal Vascular Disease. *Neurology* 1979; 29(8):1180-2.
- Donat JR. Unilateral Asterixis Due to Thalamic Hemorrhage. *Neurology* 1980; 30(1):83-4.
- Vallat JM, Rkina M, Bokor J. Unilateral Asterixis due to Subdural Hematoma. *Arch Neurol* 1981; 38(8):535.
- Feldmeyer JJ, Bogousslavsky J, Regli F. Unilateral or Bilateral Asterixis in Cases of Thalamic or Parietal Lesions: an Afferent Motor Disorder? *Schweiz Med Wochenschr* 1984; 114(5):167-71.
- Peterson DI, Peterson GW. Unilateral Asterixis. *Bull Clin Neurosci* 1986; 51:77-80.
- Peterson DI, Peterson GW. Unilateral Asterixis due to Ipsilateral Lesions in the Pons and Medulla. *Ann Neurol* 1987; 22(5):661-3.
- Masdeu JC, Gorelick PB. Thalamic Astasia: Inability to Stand after Unilateral Thalamic Lesions. *Ann Neurol* 1988; 23(6):596-603.
- Mizutani T, Shiozawa R, Nozawa T, Nozawa Y. Unilateral asterixis. *J Neurol* 1990 ; 237(8):480-2.
- Gila L, García Díaz JJ, Campos C, Gil Pujades A, Otal M. Unilateral Asterixis Associated with Anatomic Cerebral Lesions. *Rev Clin Esp* 1991; 188(7):355-7.
- Lazzarino LG, Nicolai A. Late Onset Unilateral Asterixis Secondary to Posterior Cerebral Artery Infarction. *Ital J Neurol Sci* 1992;13(4):361-4.
- Lee MS, Marsden CD. Movement Disorders Following Lesions of the Thalamus or Subthalamic Region. *Mov Disord* 1994; 9(5):493-507.
- Stell R, Davis S, and Carroll W M. Unilateral Asterixis due to a Lesion of the Ventrolateral Thalamus. *J Neurol Neurosurg Psychiatry* 1994; 57(1):116-8.

21. Nighoghossian N, Trouillas P, Vial C, Froment JC. Unilateral Upper Limb Asterixis Related to Primary Motor Cortex Infarction. *Stroke* 1995; 26:326-8.
22. Río J, Montalbán J, Pujadas F, Alvarez-Sabín J, Rovira A, Codina A. Asterixis Associated with Anatomic Cerebral Lesions: a Study of 45 Cases. *Acta Neurol Scand* 1995; 91(5):377-81.
23. Muneta S, Yamashita Y, Fukuda H, Watanabe S, Imamura Y, Matsumoto I. Asterixis and Astatic Seizures in Association with Bilateral Insular Lesions in a Patient with Viral Encephalitis. *Intern Med* 1995; 34(8):756-61.
24. Tatu L, Moulin T, Martin V, Chavot D, Rousselot JP, Monnier G, et al. Unilateral Asterixis and Focal Brain Lesions. 12 Cases. *Rev Neurol (Paris)* 1996; 152(2):121-7.
25. Tatu L, Moulin T, Martin V, Monnier G, Rumbach L. Unilateral Pure Thalamic Asterixis: Clinical, Electromyographic, and Topographic Patterns. *Neurology* 2000; 54(12):2339-42.
26. Kim JS. Asterixis after Unilateral Stroke: Lesion Location of 30 Patients. *Neurology* 2001; 56(4):533-6.
27. Velasco F, Gomez JC, Zarranz JJ, Lambarri I, Ugalde J. Asterixis in Focal Brain Lesions. *Neurologia* 2004; 19(4):225-9.
28. Klos KJ, Wijdicks EF. Unilateral Asterixis after Thalamic Hemorrhage. *Neurology* 2006; 66(2):E11.
29. Song IU, Kim JS, An JY, Kim YI, Lee KS. Co-occurrence of Astasia and Unilateral Asterixis Caused by Acute Mesencephalic Infarction. *Eur Neurol* 2007; 57(2):106-8.