



Neuroacanthocytosis in Two Brothers: An Ultra-rare Cause of Movement Disorder

Ghabeli-Juibary Ali (MD)¹, Rezaeitalab Fariborz (MD)^{2*}

ARTICLE INFO

Article type:
Case Report

Article history:

Received: 18 January 2016
Accepted: 11 June 2016
Available online: 30 June 2016
CJNS 2016; 2 (5): 50-53

1. Resident of Neurology, Student Research Committee, Department of Neurology, Faculty of Medicine, Mashhad University of Medical Sciences, Mashhad, Iran
2. Assistant Professor of Neurology, Department of Neurology, School of Medicine, Mashhad University of Medical Sciences, Mashhad, Iran

***Corresponding author:**

Assistant Professor of Neurology,
Department of Neurology, School of
Medicine, Mashhad University of
Medical Sciences, Mashhad, Iran
Email: Rezaeitalabf@mums.ac.ir

ABSTRACT

We report a rare genetic disorder case of neuroacanthocytosis with clinical profile (oro-lingual-facial abnormal involuntary movements, neuropathy) and typical magnetic resonance findings (cerebral atrophy, bilateral caudate nuclei atrophy with dilated anterior horns of the lateral ventricles), positive family history in his brother and acanthocytosis in peripheral blood smear.

Keywords: Neuroacanthocytosis; Chorea; Dystonia; Magnetic Resonance Imaging

Copyright © [2016] Caspian Journal of Neurological Sciences. All rights reserved.

➤ **Please cite this paper as:**

Ghabeli-Juibary A, Rezaeitalab F. Neuroacanthocytosis in Two Brothers: An Ultra-rare Cause of Movement Disorder. Caspian J Neurol Sci 2016; 2(5): 50-53.

Introduction

Neuroacanthocytosis syndromes are a group of genetically inherited diseases defined by red blood cell acanthocytosis accompanied with progressive degeneration of the brain basal ganglia. The core neuroacanthocytosis syndromes mainly encompass of the two diseases, chorea-acanthocytosis and the McLeod syndrome. Huntington's disease-like 2, and pantothenate kinase-associated neurodegeneration (PKAN) are very rare but these diseases can also be

incorporated in this group of syndromes (1,2). Chorea-acanthocytosis is rare, with an estimated around 1000 cases worldwide (2). This disorder is characterized by the following features: 1- onset in young adulthood of chorea and/or Parkinsonism, oro-lingual-facial dystonias, tics, social disinhibition, seizures, areflexia, and distal muscle wasting. 2- The recognizable appearance of thorny or spiky erythrocytes called acanthocytosis. The mean age of onset

was 35 years in a systemic review with a broad range from the first to the seventh decade. Initial clinical symptoms can vary widely (1-3). The main syndrome is a result of an autosomal recessive mutation. However, the other subtypes are X-linked (McLeod type) or autosomal dominant (1). The main differential diagnoses are Wilson disease and Huntington's disease (3).

Case Presentation

A 36 year old right handed married male, admitted to the neurology ward of Qaem hospital (Mashhad University of Medical Sciences) with complaint of abnormal involuntary movements. He came from a family of three brothers and five sisters with preliminary education. His problem had initiated with vocal tics, sucking, whistling and grunting from 4 years ago. The vocal disorder was superimposed by movement abnormalities including shoulder shrugs and flinging arm. His past medical and drug history was negative. On family history, we found that one of his brothers had suffered from severe gait impairment since 2 years ago.

The mental Status was normal with MMSE of 27. He had mild dysarthria with normal cranial nerves, Muscle strengths were bilaterally normal (5/5) without any atrophy on motor examination. He suffered from hyperactive, involuntary frequent, brief, sudden movement in both arms, shoulder shrugging, oromandibular abnormal involuntary movements including tongue protrusion. Examination of deep tendon reflexes (DTR) showed generalized absent DTRs. There was no Babinski sign. Sensory examination revealed mild vibration sensation impairment.

His brother on examination revealed revealed odd lurching type of gait and violent trunk spasm. Deep tendon reflexes (DTRs) were absent. The neurological examination otherwise was normal.

Complete blood count indices and serum electrolyte assays, all were in normal range in our patient. Ceruloplasmin and copper serum level were normal with mild elevation of urinary copper level. Brain magnetic resonance imaging showed cerebral atrophy, atrophy of bilateral caudate head and dilatation of anterior horn of lateral ventricles (Figure 1).

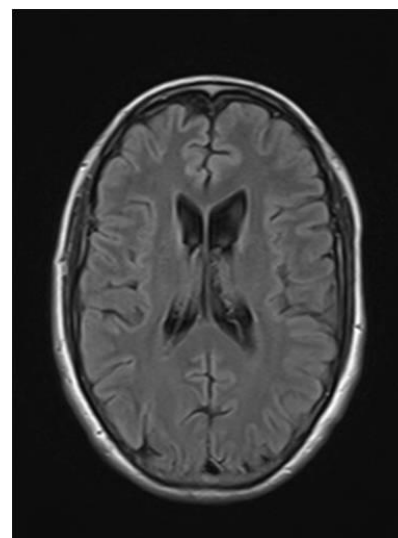


Figure1. Atrophy of the head of caudate nuclei; and cerebral atrophy in axial brain MRI

Peripheral blood smear showed 20% acanthocytosis (Figure 2).

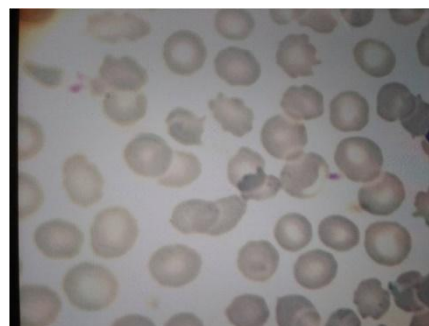


Figure2. The spiked red blood cells (acanthocytes) in peripheral blood.

Other laboratory data included mild elevation of liver enzyme (AST, ALT). Electrodiagnostic studies showed mild sensory- motor axonal polyneuropathy. Search for Kayser–Fleischer rings (KF rings) was negative on ophthalmologist consult request. Abdominal sonography searching for liver pathology was normal.

Discussion

The movement disorder is often the most prominent clinical feature of neuroacanthocytosis. Although some patients may present with Parkinsonism, chorea is the typical manifestation. Flinging arm and leg movements, shoulder shrugs, and pelvic thrusts are common presentations. Ambulation is usually severely affected with an odd lurching type of gait. Falls, violent trunk spasms and impaired postural reflexes are common (1-3).

Dystonia affecting the mouth region and pharynx are characteristic feature in these patients. Repetitive tongue protrusions, so-called “feeding dystonia”, combined with impaired swallowing can cause cachexia. Tongue and lip biting are characteristic features; patients may learn to put a towel in the mouth to prevent such self-mutilation (2-4).

Vocal tics consisting of gasping, sighing, whistling, blowing, sucking, and humming occur in most of patients (1,2).

A "frontal lobe syndrome" may occur in these patients, which may include social and sexual disinhibition, impaired decision-making capacity, impaired insight, obsessive compulsive tendencies, and self-neglect. The neuropsychiatric symptoms may present before the movement disorder (2,4-6).

Impaired memory and executive functioning are common but not invariable.

Dysarthria is common and may be a presenting symptom (4,5). Generalized tonic-clonic or partial complex seizures occur in half of patients; some patients develop epilepsy as their initial clinical manifestation (1,2). In many patients, seizures are found to originate from one or both temporal lobes (1,2). Neuropathy is often subclinical, manifesting with distal muscle wasting, depressed distal deep tendon reflexes, and mild sensory abnormalities, particularly impaired vibration sense (3,4). Subtle eye movement abnormalities may occur, such as impaired upgaze (2,3); however, our patients did not show this sign. Significant disability may occur in just a few years after onset of symptoms (1-3). Death usually occurs between the ages of 28 to 61 years (2,3). Acanthocytes usually constitute 5 to 50 percent of the circulating RBCs. Most patients have elevated serum CK levels without any clear explanation. Less commonly, LDH, AST, and ALT serum levels may be elevated (4-6). Like this patient, MR imaging may show atrophy of the caudate head and dilatation of the anterior horns of the lateral ventricles. Functional neuroimaging studies also propose the striatum as an area of primary abnormality (2-5).

Nerve conduction studies reveal features suggestive of a sensory axonal neuropathy with low SNAP amplitudes but normal conduction velocities. Motor nerve conduction studies may be entirely normal. Electromyography divulges evidence of chronic denervation with reinnervation (3-8). The diagnosis is based on recognizing the characteristic clinical features with peripheral acanthocytosis and normal lipid studies. Follow-up mutational analysis of the genes can be performed, however, this is

challenging due to the large size of the gene and the heterogeneity of mutation sites. Molecular genetic testing for corresponding mutations is not widely available (9-11). No curative or disease modifying therapy for neuroacanthocytosis exists. Treatment is aimed at symptom management. A multidisciplinary approach to disease management is suggested (1,2).

Conclusion

The diagnosis of Neuroacanthocytosis in this case could be considered based on characteristic clinical features like oromandibular abnormal movements with peripheral blood acanthocytosis and normal lipid studies with positive family history in his brother. As noted in this case, the disease picture exists from the purely neurological features to pathology in the hematological domains in the same patient. All presentations comprise a single syndrome. Though in such cases genetic studies are desired because we could not perform these due to paucity of resources.

Conflict of Interest

The authors have no conflict of interest.

References

1. Walker RH. Untangling the Thorns: Advances in the Neuroacanthocytosis Syndromes. *J Mov Disord* 2015;8(2):41-54.
2. Lossos A, Dobson-Stone C, Monaco AP, Soffer D, Rahamim E, Newman JP, et al. Early Clinical Heterogeneity in Choreoacanthocytosis. *Arch Neurol* 2005; 62:611-4.
3. Hardie RJ, Pullon HW, Harding AE, Owen JS, Pires M, Daniels GL, et al. Neuroacanthocytosis. A Clinical, Haematological and Pathological Study of 19 Cases. *Brain* 1991; 114 (Pt 1A):13-49.
4. Jung HH, Danek A, Walker RH. Neuroacanthocytosis Syndromes. *Orphanet J Rare Dis* 2011;25;6:68
5. Bruce LJ, Kay MM, Lawrence C, Tanner MJ. Band 3 HT, a Human Red-cell Variant Associated with Acanthocytosis and Increased Anion Transport, Carries the Mutation Pro-868-->Leu in the Membrane Domain of Band 3. *Biochem J* 1993; 293 (Pt 2):317-20.
6. Bosman GJ, Bartholomeus IG, De Grip WJ, Horstink MW. Erythrocyte Anion Transporter and Antibrain Immunoreactivity in Choreoacanthocytosis. A Contribution to Etiology, Genetics, and Diagnosis. *Brain Res Bull* 1994; 33(5):523-8.
7. Stevenson VL, Hardie RJ. Acanthocytosis and Neurological Disorders. *J Neurol* 2001;248(2):87-94.
8. Walker RH, Jung HH, Danek A. Neuroacanthocytosis. *Handb Clin Neurol* 2011;100:141-51.
9. Asano K, Osawa Y, Yanagisawa N, Takahashi Y, Oshima M. Erythrocyte Membrane Abnormalities in Patients with Amyotrophic Chorea with Acanthocytosis. Part 2. Abnormal Degradation of Membrane Proteins. *J Neurol Sci* 1985; 68(2-3):161-73.
10. Dobson-Stone C, Velayos-Baeza A, Filippone LA, Westbury S, Storch A, Erdmann T, et al. Chorein Detection for the Diagnosis of Chorea-acanthocytosis. *Ann Neurol* 2004; 56(2):299-302.
11. Danek A, Dobson-Stone C, Velayos-Baeza A. The Phenotype of Chorea-acanthocytosis: a Review of 106 Patients with *VPS13A* Mutations. *Mov Disord* 2005;20:1678.